

In the name of God

Mucormycosis

Dr.h.mazaherpour

Assistant professor of infectious disease AUMS

- A 38-year-old male was admitted to our Hospital, a tertiary care center with a history of fever for 4 days. He presented with a high grade fever, body ache, cough and shortness of breath. Nasopharyngeal swab was sent for RT-PCR which came positive and a diagnosis of COVID-19 was confirmed.
- The patient had no history of diabetes or any other debilitating conditions and no relevant family history.

- On admission, the deranged investigations were: Neutrophil count 83.1% (35–66%), Lymphocyte count 9.5% (24–44%), Fasting blood sugar (FBS) 98 mg/dL (70-110 mg/dL), Post-prandial blood sugar (PPBS) 146 mg/dL (110-140 mg/dL), HbA1c 6.3% (<6%), Serum Interleukin-6 37.93 pg/mL (<6.4 pg/mL), CRP 17.84 mg/L (0–6 mg/L), D-Dimer 460 ng/mL (0–500 ng/mL).

- He was monitored in the Intensive Care Unit for 5 days and was started on Inj.Remdesivir IV with a loading dose of 200 mg, followed by 100 mg daily for 11 days. Methylprednisolone was given by IV infusion, 80 mg/day in 240 mL saline at 10 mL/h for 18 days. Also Inj.Dexamethasone 4 mg twice daily was given for 12 days as a part of COVID-19 management. Post-treatment FBS 125 mg/dL, PPBS 352 mg/dL and HbA1c 12.3%

- After 18 days, the patient complaint of swelling and pain in the left eye. He was referred to the Department of Head and Neck Oncology for the same. On clinically examination, there was malaise, proptosis, chemosis, periorbital cellulitis and restricted medial gaze. Visual acuity was 6/6 with partial ophthalmoplegia and no nasal discharge was seen

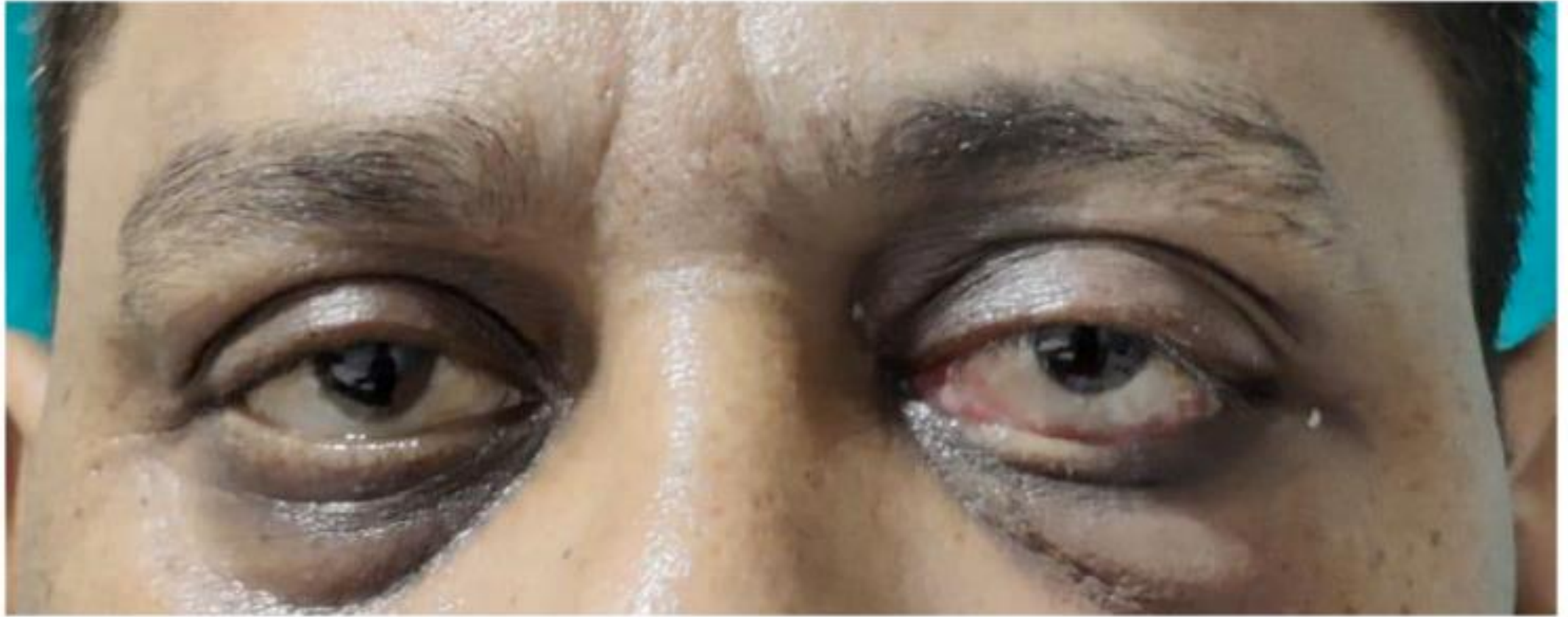

Fig. 1. Preoperative photograph showing left eye exophthalmous and chemosis.

- MRI brain & orbit was done showing an ill-defined heterogenous soft tissue signal intensity (hypointense on T1W-imaging), polypoidal mucosal thickening involving left maxillary and ethmoid sinuses was seen. There was displacement of adjacent medial and inferior rectus. Retrobulbar soft tissue fat stranding and edema with resultant displacement of left eye ball anteriorly leading to proptosis was seen. It was also found to be closely abutting the left optic nerve

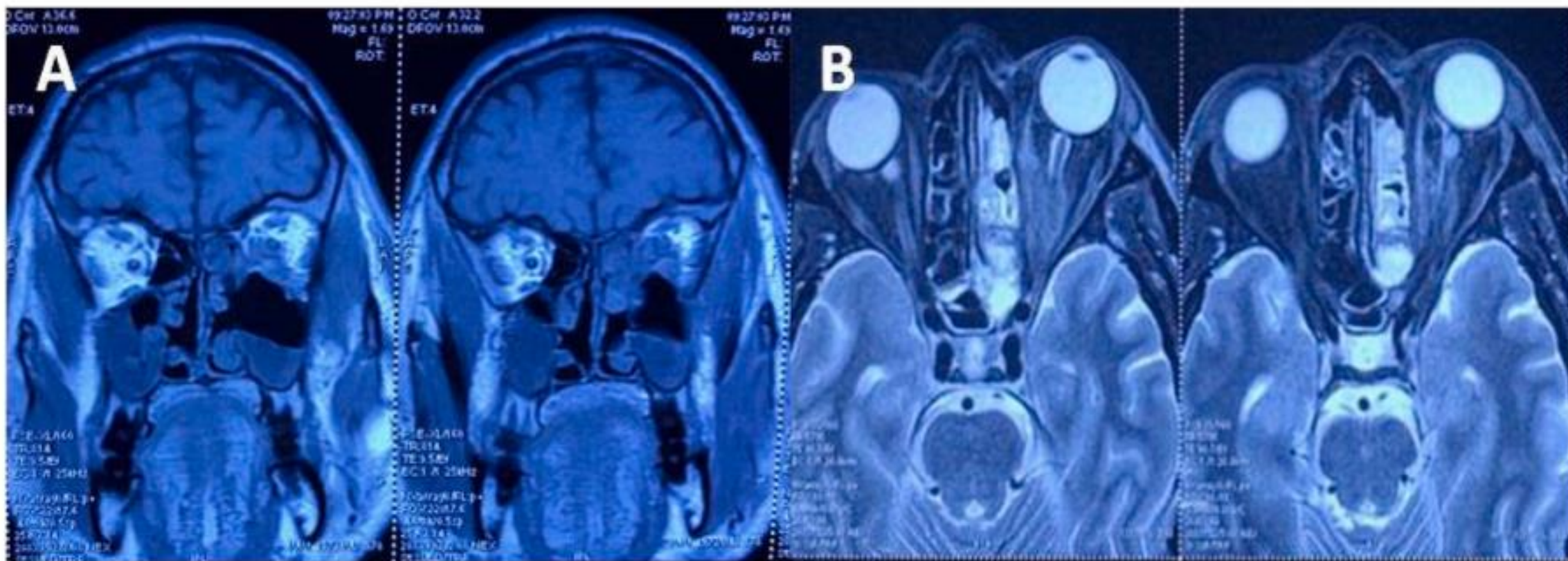
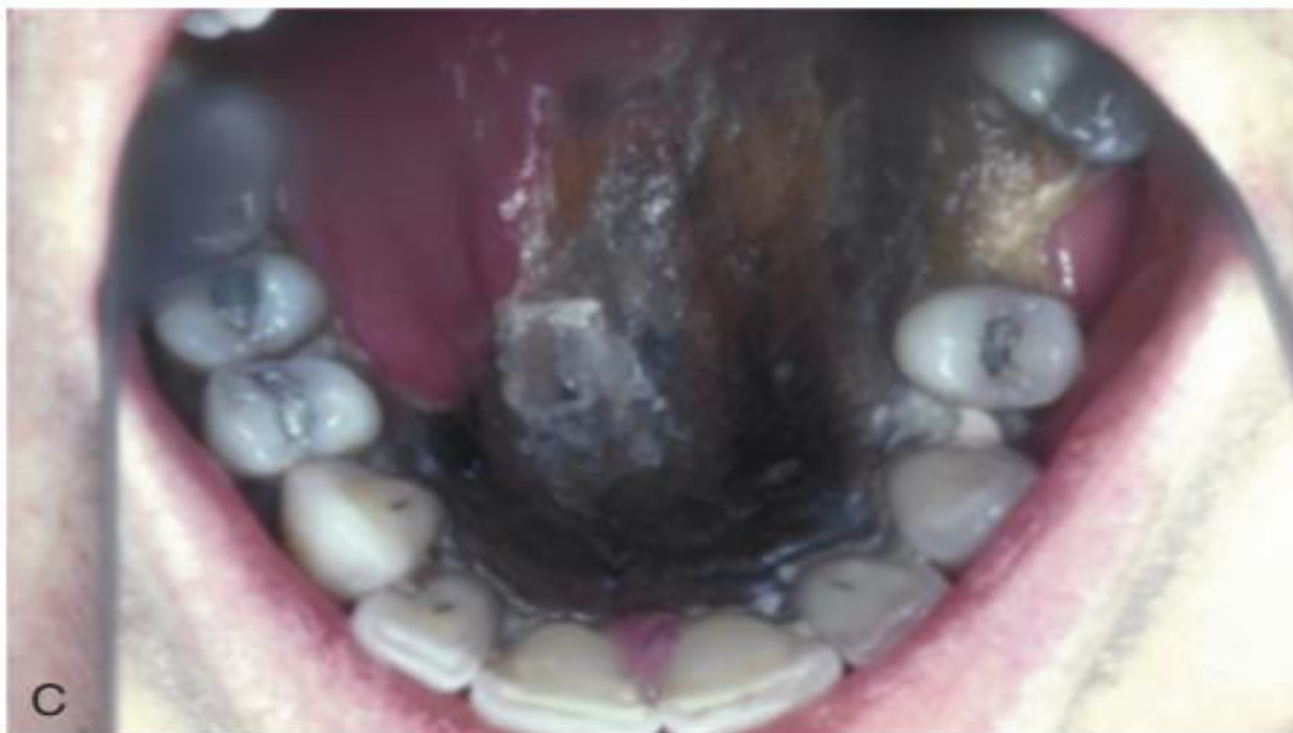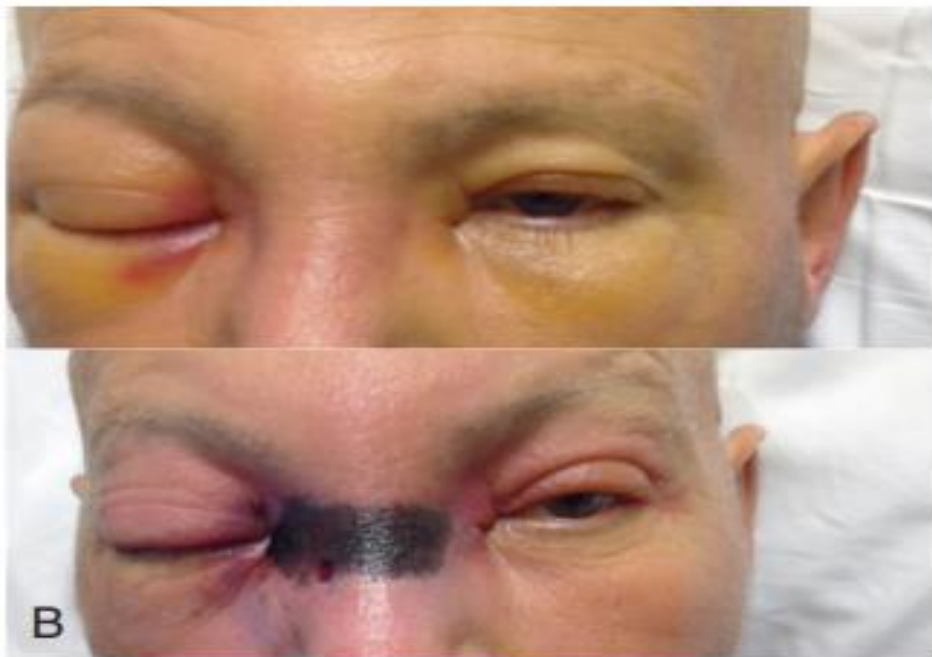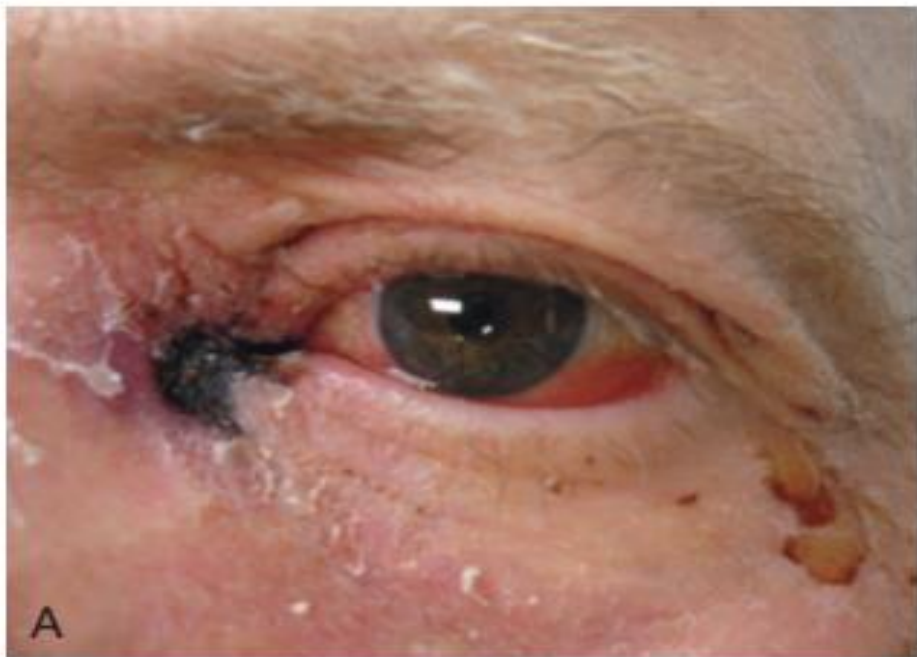
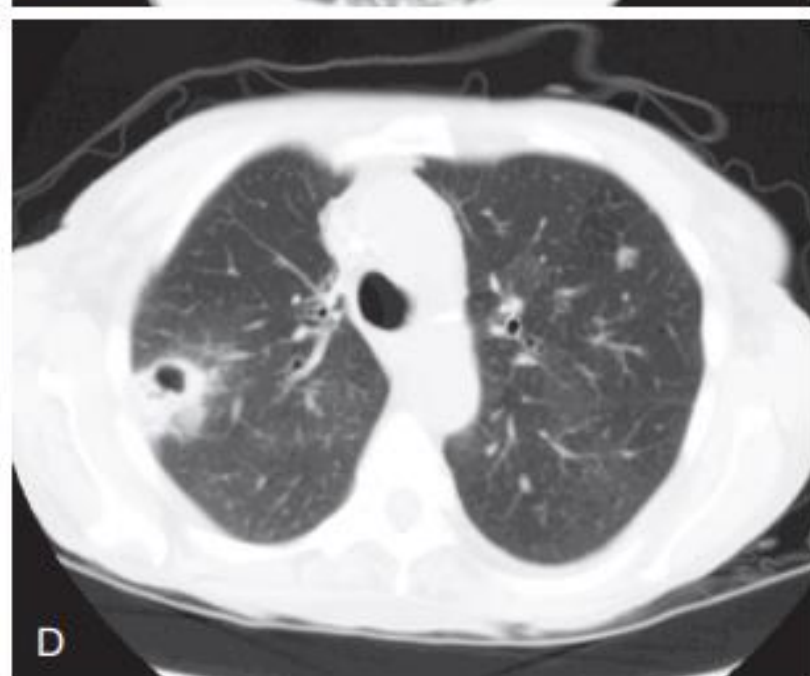
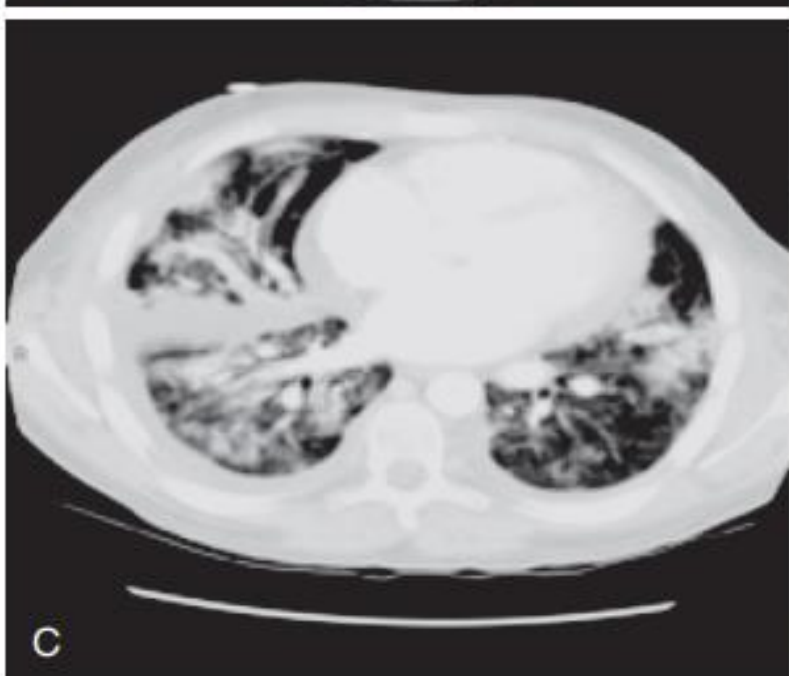
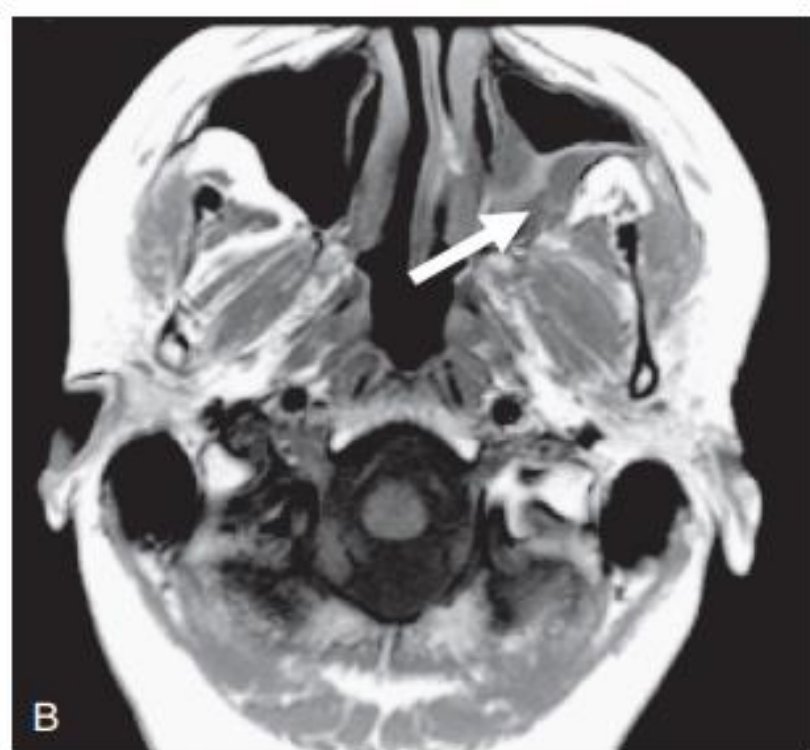


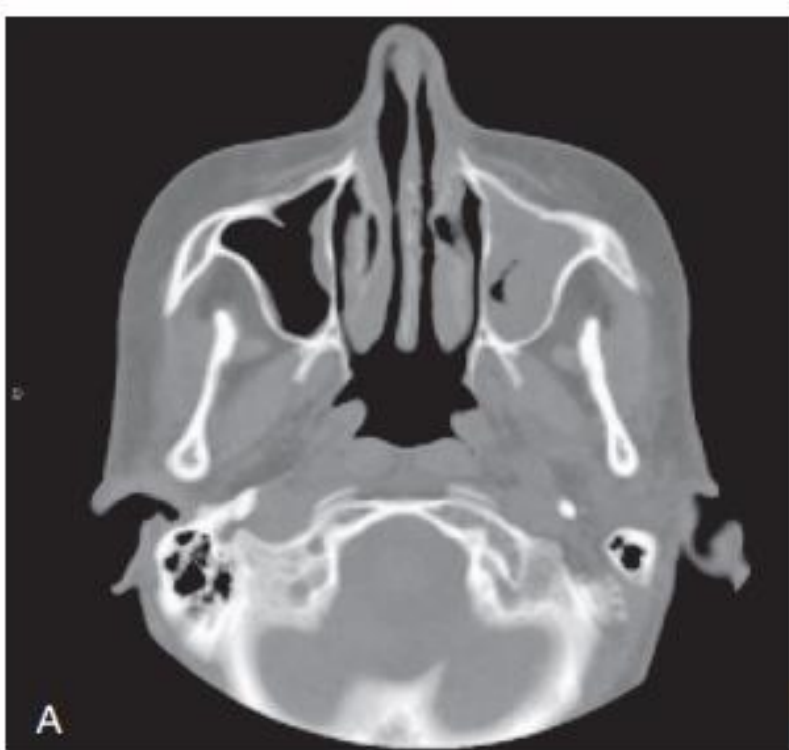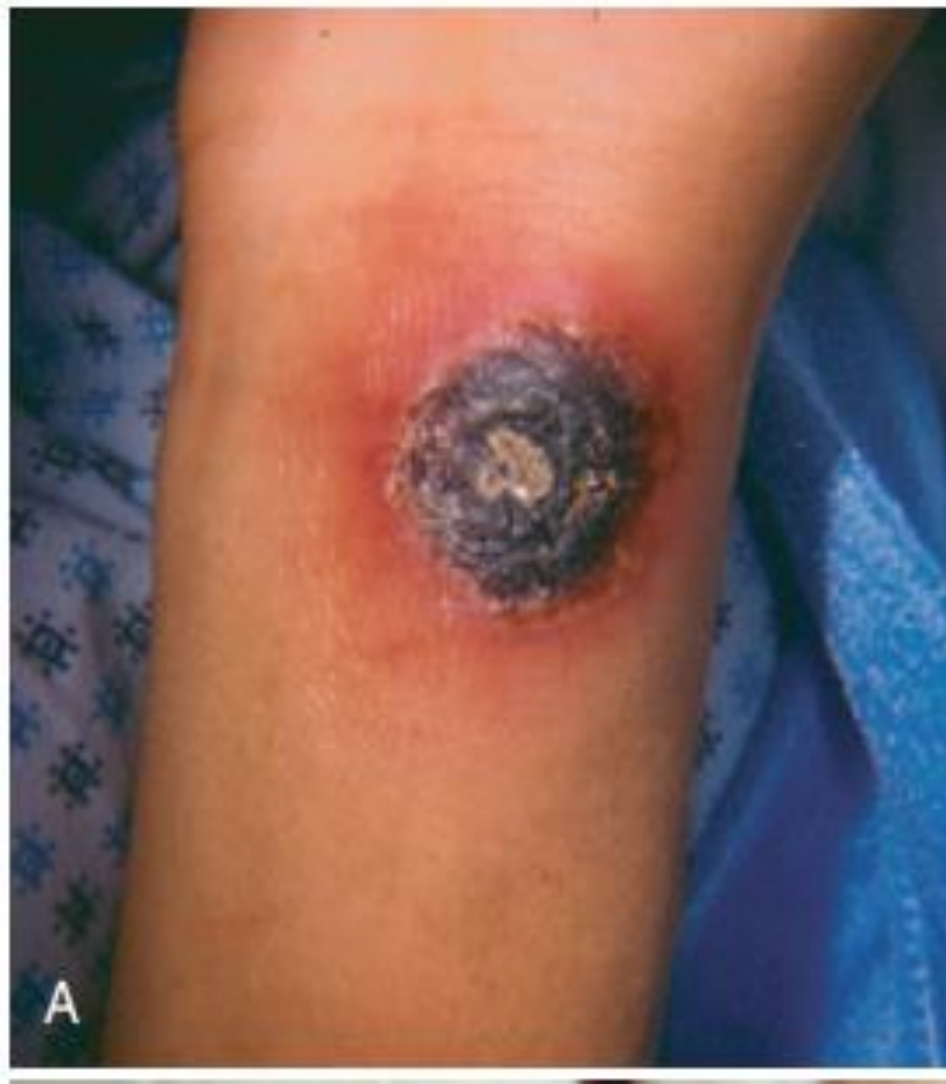Fig. 2. (A) Coronal Section of MRI T1 weighted image and (B) Axial Section of MRI T2 weighted image showing extension of the lesion.

- Crusting was noted over posterior aspect of inferior turbinate, septum and conchae. The sinuses were debrided and the specimen obtained was sent for culture sensitivity and histopathology.
- On histopathology examination, aseptate broad based hyphae and gram positive bacilli were seen and hence Mucormycosis suspected.
- The medical regime changed to Inj. Amphotericin B 300 mg/day, eyedrops Tobramycin BD







mucormycosis

- Agents of mucormycosis are ubiquitous fungi in the environment that are commonly found in decaying organic substrates, including bread, fruits, vegetable matter, soil, compost piles, and animal excreta. These fungi characteristically produce large, ribbon-like hyphae that are irregular in diameter with only occasional septae, hence the characterization of these organisms as aseptate fungi.

- Spores ranging from 3 to 11 μm in diameter are easily aerosolized and dispersed and cause infections in humans when inhaled or introduced through a cutaneous or percutaneous route.
- **Acquisition of Infection**
The primary mode of acquisition of mucormycosis is inhalation of spores from environmental sources. Trauma, penetrating wounds, burns, and direct injection of sporangiospores can cause infection through a cutaneous or percutaneous route.

- **Patient Populations at Risk** The populations most commonly at risk for mucormycosis include patients with poorly controlled diabetes mellitus, prolonged neutropenia, high-dose corticosteroid treatment, or immunosuppressive therapy associated with transplantation, and/or elevated levels of free iron, which enhances fungal growth
- Patients who develop mucormycosis in the absence of underlying disease or immunosuppression at the time of infection frequently have histories of penetrating trauma, burns, surgery, or illicit IV drug use before the infection.

- **Rhinocerebral Infections**

Rhinosinusitis, rhino-orbital, and rhinocerebral infections are classic manifestations of human mucormycosis. Infection is initially localized to the nasal turbinates and paranasal sinuses after inhalation of spores but can rapidly progress to the orbit (sino-orbital) or brain (rhinocerebral), particularly in patients with diabetic ketoacidosis or profound neutropenia.

- **Clinical Presentation** Initial symptoms of sinus invasion by mucormycosis are indistinguishable from other more common causes of sinusitis. Sinus pain, congestion, headache, mouth or facial pain, otologic symptoms, and hyposmia or anosmia are common
- Involved tissues become red, then violaceous, and finally black with thrombosis and tissue necrosis. Necrotic eschars of the nasal cavity and turbinates, facial lesions around the nose, and exophytic or necrotic lesions of the hard palate extending from the maxillary sinus are signs of rapidly progressing infection.

- Extension of sinus disease is primarily into contiguous structures. Maxillary sinus infection extends into the hard palate, nasal cavity, and ethmoid sinus. Sphenoid disease invades the cavernous sinus, contiguous temporal lobe, and internal carotid artery in the siphon. Septic emboli from the carotid artery into the frontal and parietal lobes can occur.
- Ethmoid sinus disease may invade the face or frontal lobe but easily crosses the lamina papyracea into the orbit.

- Periorbital edema, ptosis, proptosis, chemosis, and preseptal and orbital edema are early signs of orbital extension. Pain and blurring or loss of vision often indicate invasion of the globe or optic nerve.
- Patients with extensive rhino-orbital or rhinocerebral disease may present with trigeminal and ocular motor nerve palsy after cavernous sinus invasion
- A bloody nasal discharge may be an early sign of nasal mucosal invasion.

- **Radiology**

Radiographic imaging is often suggestive of severe sinusitis but lacks the specificity to diagnose rhinocerebral mucormycosis. Computed tomography (CT) of the sinuses typically reveals mucosal thickening, air-fluid levels, and bony erosion

- Extraorbital muscle thickening is often the first sign on CT or MRI of orbital involvement and should prompt empirical antifungal therapy until surgical exploration or biopsy of the sinus and orbits can be performed, which should be done as soon as possible.

TREATMENT

- Successful treatment of mucormycosis relies on timely diagnosis, reversal of underlying predisposing factors, early surgical débridement of infected tissue, and rapid initiation of effective high-dose systemic antifungal therapy.
- Early diagnosis is critical to the outcome of mucormycosis because small focal lesions can be surgically resected before the lesions progress to involve critical structures or distal organs

- Patients with suspected rhinocerebral mucormycosis should undergo a thorough examination and “staging” of their disease, including CT of the paranasal sinuses and lungs as well as endoscopic examination of nasal turbinates with biopsy of any suspicious lesions or necrotic eschars.

- Rapid correction of predisposing conditions, such as control of hyperglycemia, reversal of ketoacidosis, and rapid tapering of glucocorticoid therapy, are critical for reversing conditions that favor fungal virulence and dissemination.

Antifungal Therapy

- Historically, the drug of choice for the treatment of mucormycosis was conventional amphotericin B deoxycholate (ABD), administered at the maximal tolerated doses of 1 to 1.5 mg/kg/day.
- Unfortunately, high doses of conventional amphotericin B are usually not tolerated for more than several days before renal function deteriorates, especially in patients with diabetes or receiving concomitant nephrotoxic therapies.

- **Lipid Amphotericin B Formulations** Lipid formulations of amphotericin B are safer than ABD for long-term administration and, in our opinion, are the preferred first-line treatment for severe mucormycosis.
- In one of the few published case series, 24 patients with mucormycosis and diabetes as the predominant underlying risk factors were treated with ABLC after failure or intolerance of the conventional ABD formulation

- The overall response rate (improvement or cure of infection) was 71% , with few reported toxic effects, even in patients with preexisting renal dysfunction.
- Several case series have reported the successful treatment of mucormycosis with the liposomal formulation of amphotericin B, sometimes administered at high doses (i.e., 10 mg/kg/day) for prolonged treatment courses

- The optimal dosing approach for L-AMB in patients with mucormycosis is frequently debated. Preclinical pharmacokinetics/pharmacodynamics studies in murine models of pulmonary mucormycosis that simulated human dosing have suggested that ABLC at 5 mg/kg/day or L-AMB at 10 mg/kg/day results in rapid antifungal accumulation in the lung, reduced fungal burden, and improved survival.

- In one of the few randomized trials that compared standard doses of L-AMB (3 mg/kg/day) to a higher dose-regimen (10 mg/kg/day for 14 days, then 3 mg/kg/day) for invasive aspergillosis, patients randomized to the higher-dosed L-AMB regimen failed to achieve higher response rates but experienced significantly higher rates of nephrotoxicity and severe hypokalemia

- The feasibility of high-dose (10 mg/kg/day) L-AMB treatment for the initial treatment of mucormycosis was explored in a multicentric prospective French study of 40 patients with invasive mucormycosis. The planned treatment of 10 mg/kg/day was administered as an infusion of at least 2 hours for 4 weeks.

- Of importance, although 4 weeks of high-dose L-AMB was planned, the average treatment duration at this dose was 13.5 days (range, 0–28), with 40% of patients experiencing a doubling in the baseline serum creatinine and severe hypokalemia (serum potassium <3 mmol/L).
- Therefore considerations for using doses of L-AMB higher than 5 mg/kg/day should take into account that a sizable proportion of patients will develop renal injury requiring dosage reduction or possibly a switch to triazole therapy after the first 1 to 2 weeks of therapy.

Triazoles

- The prospects for using posaconazole in the treatment of mucormycosis has improved with the introduction of an extended-release tablet formulation with improved bioavailability compared with the older suspension, and an IV formulation solubilized in sulfobutyl ether β -cyclodextrin.
- In an open-label study evaluating posaconazole as salvage therapy (not initial therapy), the overall success rate of posaconazole (800 mg/day) was 70% in 24 patients, and it was well tolerated with only minimal GI side effects.

- At present the US Food and Drug Administration (FDA) has not approved posaconazole for primary or salvage therapy of mucormycosis, indicating the need for further studies.
- The extended-release tablet formulation of posaconazole is administered at a dose of 300 mg (three 100-mg delayed-release tablets) twice a day on the first day, then 300 mg daily.

- Although the absorption of the tablets is improved with food, the tablets have adequate bioavailability even in patients with poor dietary intake or receiving acid-suppression therapy, such as a proton pump inhibitor.
- The IV formulation of posaconazole is dosed at 300 mg IV twice daily on day 1, followed by 300 mg daily thereafter,

- Although therapeutic drug monitoring has been recommended for posaconazole in *Aspergillus* treatment guidelines to ensure serum trough levels greater than 1.5 mg/L during the treatment of infection, a similar relationship between serum trough levels of posaconazole and outcome of mucormycosis has not been reported.
- In 2015 the FDA approved isavuconazole for treatment of invasive mucormycosis

- Isavuconazole may be a possible alternative to posaconazole or L-AMB, particularly for longer-term therapy.
- An advantage of isavuconazole is that it is administered as a prodrug formulation (isavuconazonium) in either an IV and oral formulation with excellent bioavailability that is not affected by dietary intake or acid-suppression therapy.

- Isavuconazole is dosed with a 372-mg loading dose administered every 8 hours for 6 doses (48 hours), then a 372-mg maintenance dose daily.
- Isavuconazole is generally well tolerated, making it a possible alternative for patients who are clinically stable and have limiting drug interactions with posaconazole or cannot tolerate the nephrotoxic effects of L-AMB.

- Isavuconazole is available in oral and IV formulations and presents some advantages: linear pharmacokinetics, few interactions with cytochrome P450 isoenzymes leading to few drug– drug interactions, QT decrease, no nephrotoxic cyclodextrin in the IV formulation (different from posaconazole IV form), no need for dose adjustment in kidney or liver failure and in obesity, and excellent oral bioavailability with no food requirements

- Concentration of ISZ in the necrotic center of brain abscess has been shown low, but concentration in inflammatory brain tissue surrounding the abscess was adequate, equivalent to predicted plasma concentration
- Routine therapeutic drug monitoring (TDM) is strongly recommended for patients treated by PSZ . Serum trough PSZ concentrations of 1.5 mg/L or higher are recommended. However, there is currently no conclusive evidence for routine TDM with ISZ.

New antifungal drugs

- Some new antifungal drugs are under clinical evaluation include Rezafungin, SCY-078, orlofim, and encochleated amphotericin B . Rezafungin, a new echinocandin has not been tested against *Mucorales*. SCY-078, member of a new glucan synthase inhibitor subclass is poorly or not active against *Mucorales*. Olorofim is a member of the orotomides, a new antifungal class inhibiting dihydroorotate dehydrogenase (DHODH), a key enzyme in pyrimidine biosynthesis. It is also poorly active against *Mucorales*.

- Encochleated amphotericin B is a new oral formulation of amphotericin B. It has been shown to be well-tolerated, and is currently tested for cryptococcosis treatment in developing countries (clinical trial 161 NCT04031833). No studies on *Mucorales* efficacy are available.

Combination Therapy

- Successful treatment of mucormycosis with combinations of amphotericin B, terbinafine, rifampicin, L-AMB, posaconazole, and echinocandins has also been described in small case series and case reports.
- One of the largest case-control studies evaluating the possible benefits of combination therapy for invasive mucormycosis was performed at MD Anderson Cancer Center, which identified 47 patients who received early L-AMB monotherapy and 59 patients who received combination treatment. There was no difference in mortality between 2 groups of combination and monotherapy.

- The most common combination regimens were L-AMB plus an echinocandin (46%), L-AMB plus posaconazole (27%), or triple combination therapy (27%).
- The investigators could not identify any survival benefit for combination therapy over timely administration of L-AMB, even after propensity score adjustment

Treatment Duration

- The duration of treatment required for mucormycosis is highly individualized to the patient. Near normalization of radiographic imaging, negative biopsy specimens, and cultures from the affected site and recovery from immunosuppression are indicators that a patient is a candidate for stopping antifungal therapy
- Late relapses of mucormycosis after successful treatment have been reported several years after discontinuation of secondary posaconazole prophylaxis or onset of new immunosuppression

- Therefore continued follow-up of patients is critical in any patient who discontinues treatment for mucormycosis.
- **Prophylaxis** Because mucormycosis is a relatively rare infection, primary prophylaxis is generally not recommended. Secondary prophylaxis is often desired in patients requiring further immunosuppression after treatment for mucormycosis.

- Posaconazole, and possibly isavuconazole, appears to be a safe option for patients who require continuous, oral long-term antifungal therapy because they remain at high risk for relapsing infection
- **Adjunctive Therapies** Patients with profound neutropenia and progressive mucormycosis despite optimal therapy may be candidates for neutrophil transfusion. With currently available techniques, more than 10^{10} granulocytes can be infused, resulting in an immediate postinfusion absolute neutrophil count usually exceeding $1000/\mu\text{L}$.

- Hyperbaric oxygen therapy was reported to be a beneficial adjunct to standard surgical and antifungal therapy for mucormycosis, particularly for diabetic patients with rhinocerebral disease.
- Although this is not one of the approved uses of hyperbaric oxygen, the increased oxygen pressure achieved with hyperbaric oxygen may improve neutrophil activity and the putative oxidative killing effects of polyene antifungals.

- Multiple immune-augmentation strategies have been proposed for mucormycosis, including administration of cytokines that enhance phagocytic activity, such as granulocyte colony-stimulating factor, granulocyte-macrophage colony-stimulating factor, or IFN- γ alone or in combination with granulocyte transfusions.

- **Prognosis** The site of infection and underlying host factors are the key prognostic determinants of mucormycosis outcome. Active hematologic malignancy, allogeneic HSCT, and disseminated infection are associated with poor outcome.
- However, earlier diagnosis of the disease and aggressive treatment have been associated with improved survival rates in recent series.

- Correction of underlying immune impairment (e.g., rapid tapering of glucocorticoids), combined with aggressive multimodality treatment approaches, offer the best chance for patient survival.

Thanks for your attention