



# **Apically Repositioned Flap for crown lengthening**

Dr. Fateme Tashakor

# Treatment options

Sufficient width of attached gingiva: gingivectomy/ APF

Insufficient width of attached gingiva: APF / FGG

# The choice of therapies to increase the width of attached gingiva :

## 1. Partial-thickness apically positioned flap surgery

thick keratinized gingiva

oral vestibule has sufficient depth.

## 2. Free gingival grafts or connective tissue grafts

keratinized gingiva is completely absent

## 3. Free gingival grafts

1-2 mm of keratinized gingiva exists but underlying marginal alveolar bone is extremely thin.

Both partial-thickness, apically positioned flap surgery and free gingival grafts produce sufficient width;

however, free gingival grafts better prevent recession of the gingival margin than do partial-thickness, apically positioned flaps.

# **Apically Repositioned Flap**

# Definition:

Apically repositioned flap surgery, in which flaps are reflected and **sutured apical** to the preoperative position.

**Advantages:** maximizing the postoperative keratinized attached tissue, increased access to the alveolar bone, faster and more comfortable wound healing, and more predictable placement of the margin of gingiva.

# History

**Nabers** introduced the concept of repositioning the attached gingiva; the full-thickness flap was displaced apically to increase the attached gingiva.

**Friedman** called the procedure the **apically repositioned flap**.

# Apically positioned flap types

## Full-thickness flap

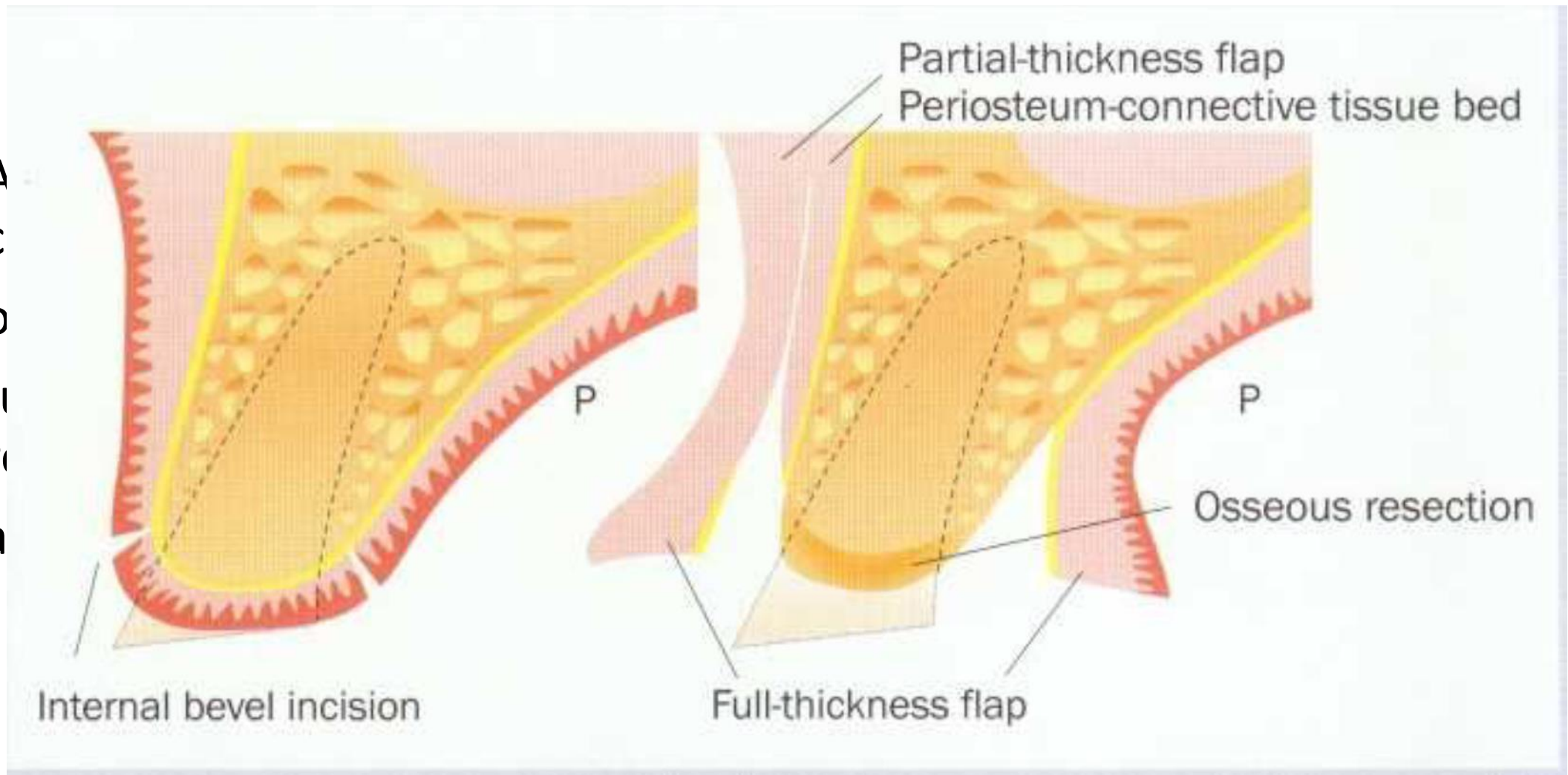
In the case of an osseous defect, it is necessary to make a full-thickness flap to ensure the accessibility of instruments to the osseous defect area

## Partial-thickness flap

partial-thickness is considerably limited clinically, so sufficient gingiva thickness is essential for good results.

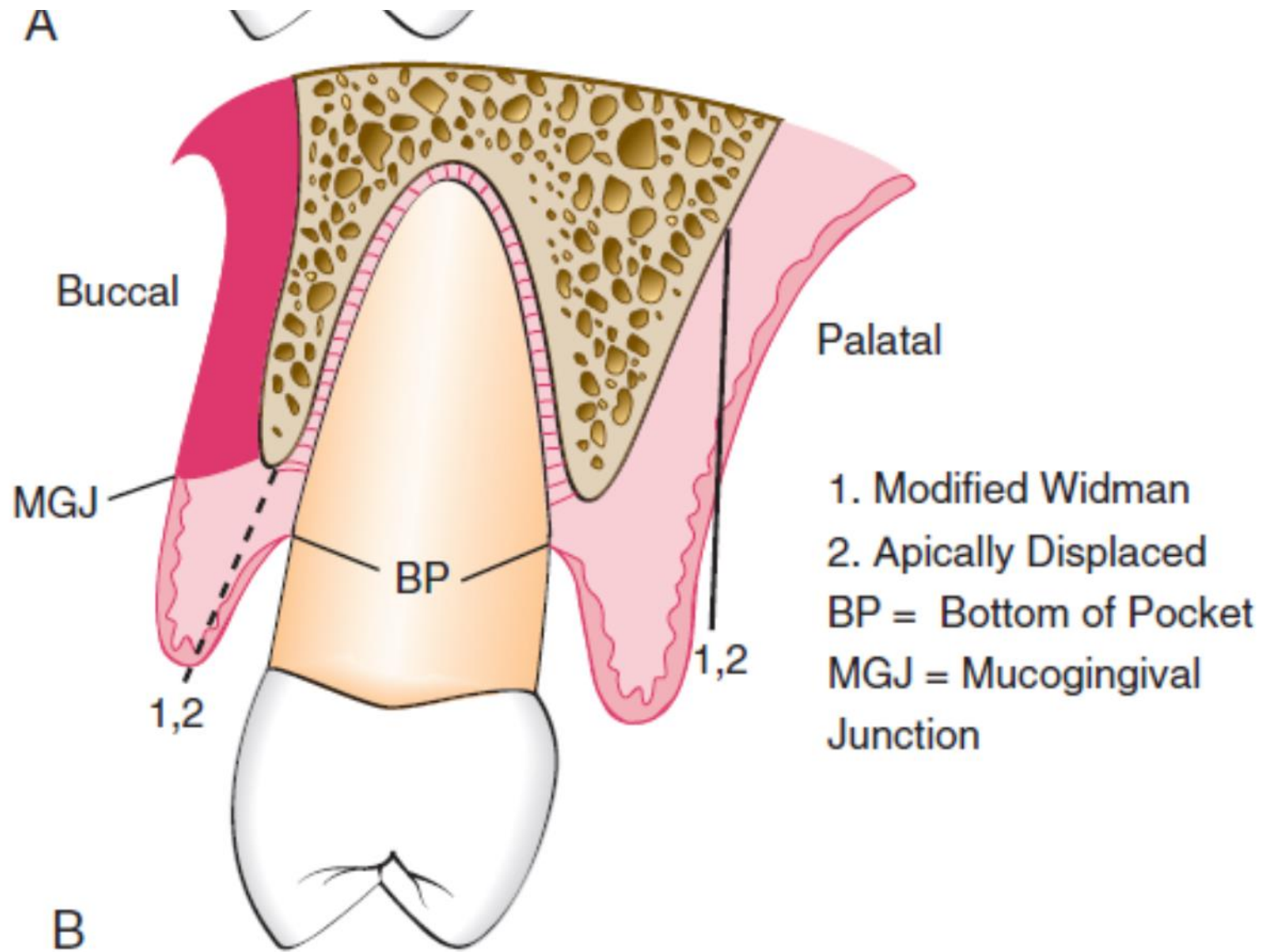


A  
C  
O  
f  
r  
a



# Technique: Accc

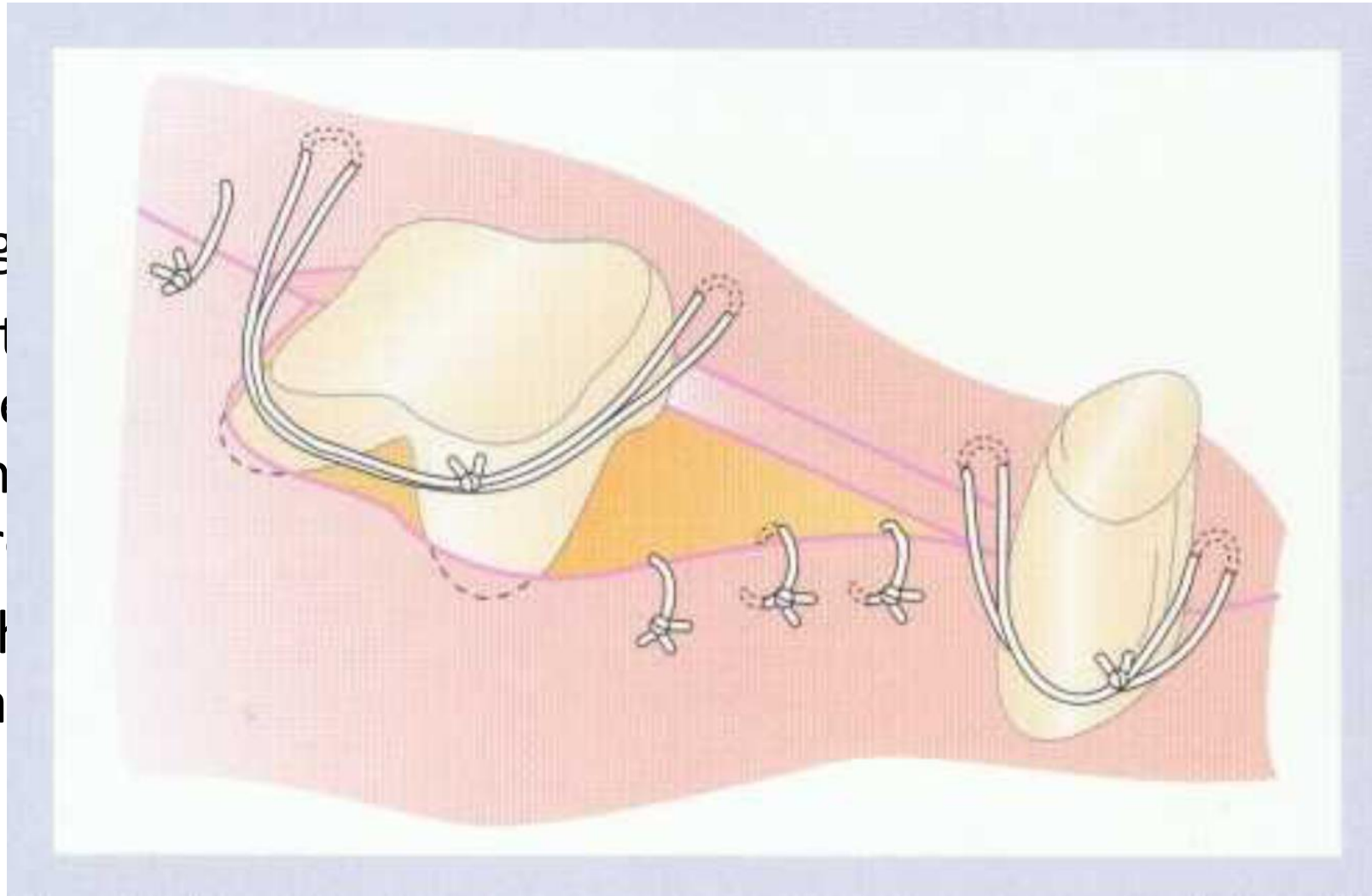
- 1- An internal bevel incis
- 2- Then Crevicular incisio
- 3- Vertical incisions are t  
junction. to provide ade  
displacement.
4. Reflection :full / partic



5- removal  
performing

6- If a full  
tooth prev  
desired, an  
coronal dir

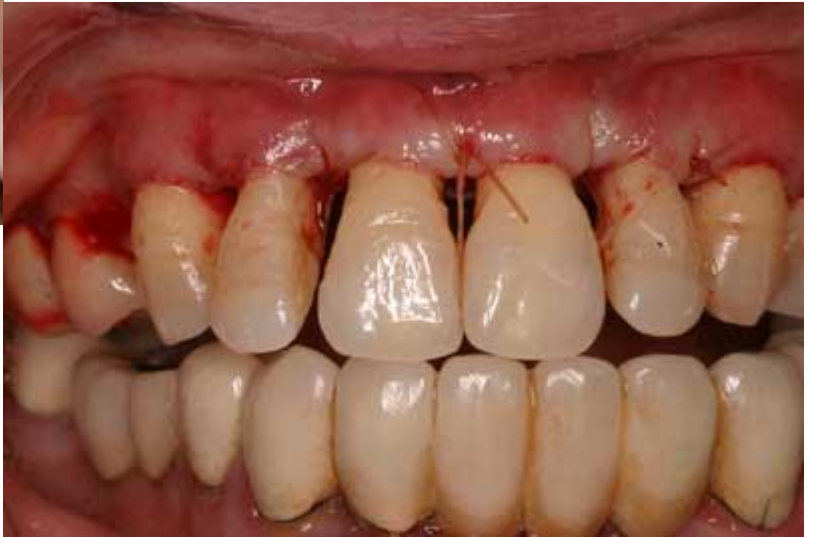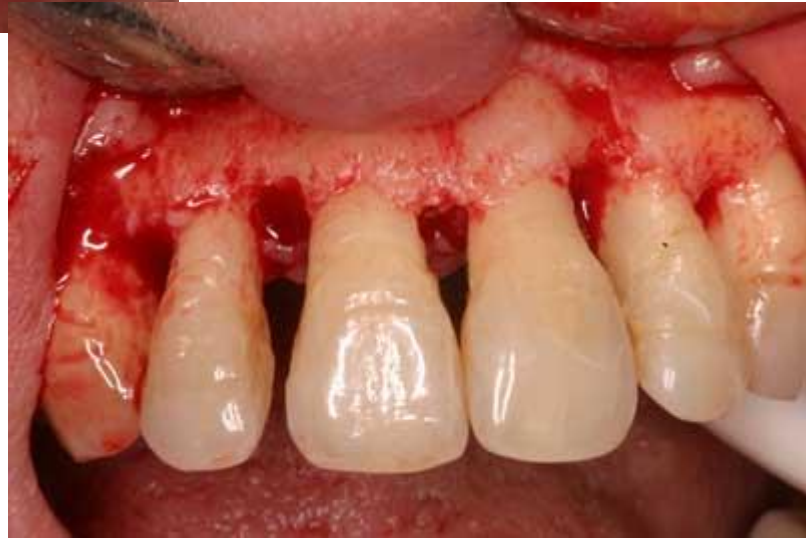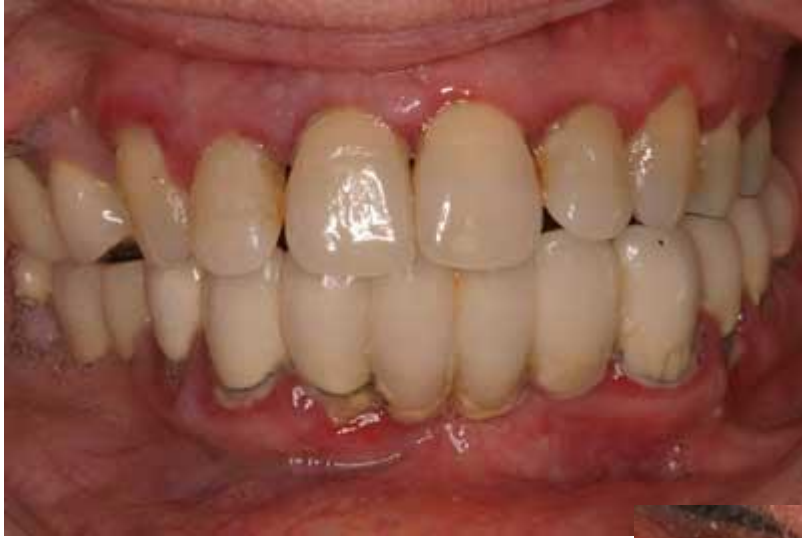A partial th  
**suture** or a



nd  
illy.

re  
an  
a

**ct loop**



# **The apically positioned flap technique for crown lengthening**

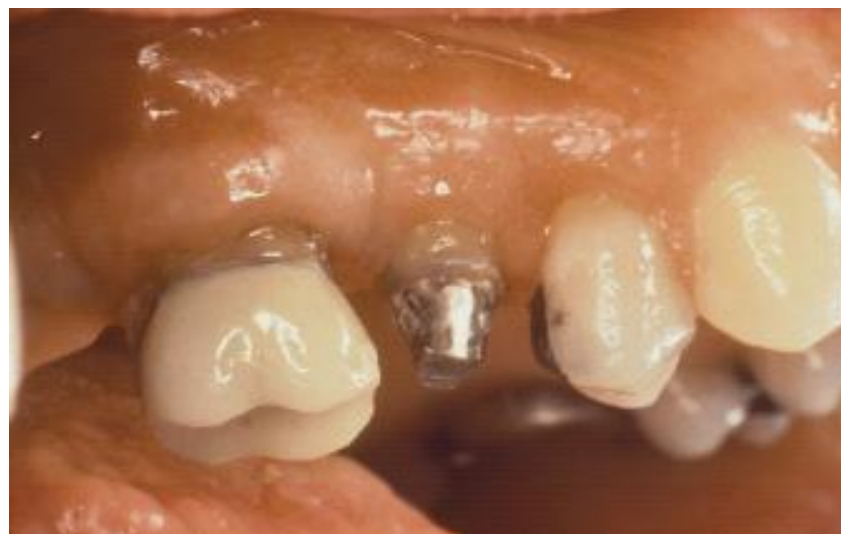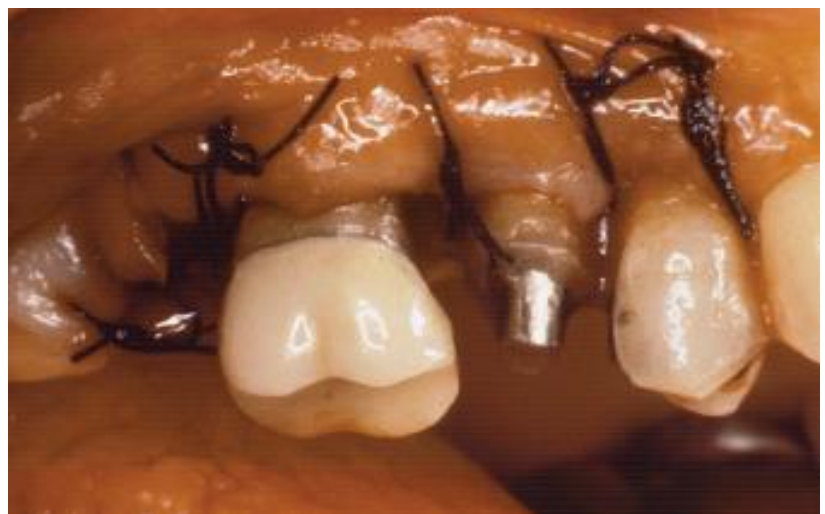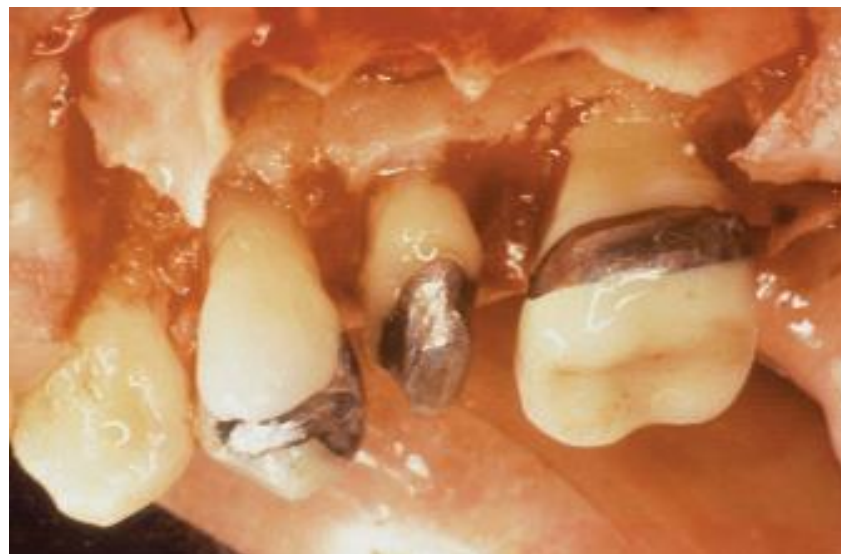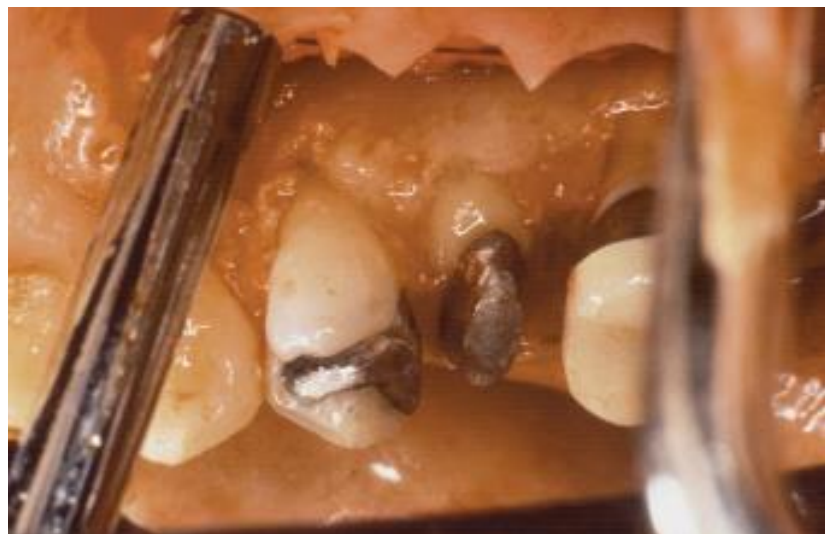# Therapies for crown lengthening

Gingivectomy

Apically repositioning flap with/without osseous resection

Forced eruption with/without fibrotomy

# Crown lengthening aim



# The apically positioned flap technique for crown lengthening

The APF with bone recontouring (resection) may be used to expose sound tooth structure. As a general rule, at least 4 mm of sound tooth structure must be exposed at time of surgery. During healing the supracrestal soft tissues will proliferate coronally to cover 2-3 mm of the root

thereby leaving only 1-2 mm of supragingivally located sound tooth structure zone.



# Indication

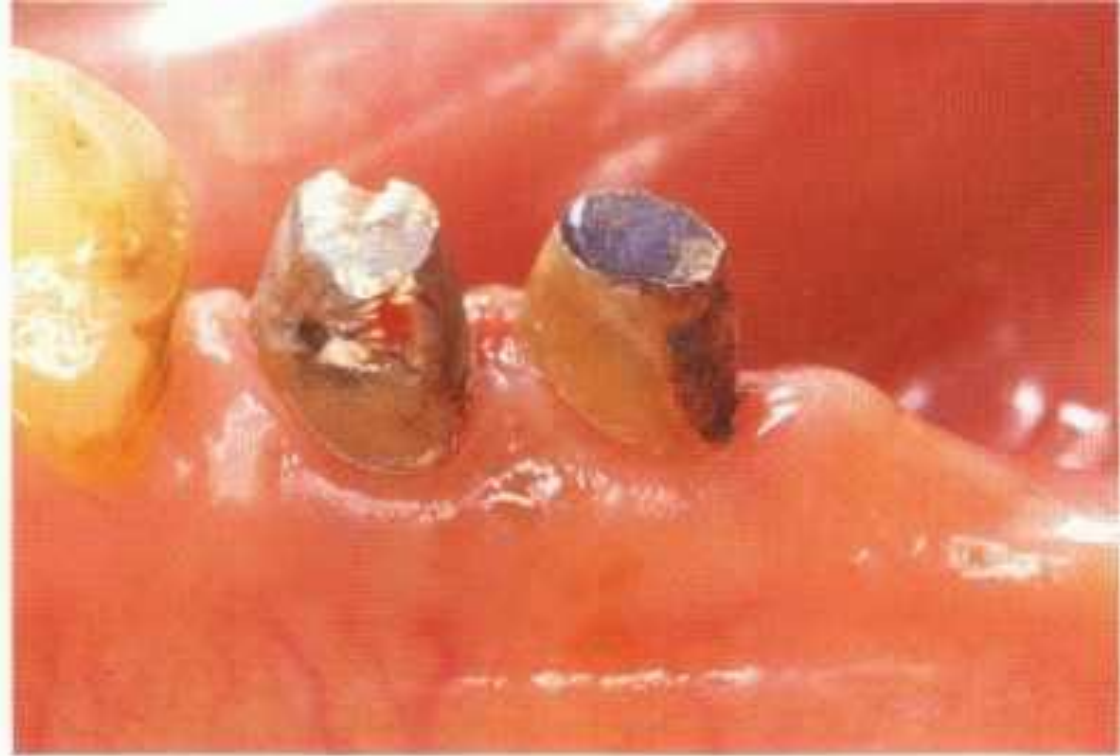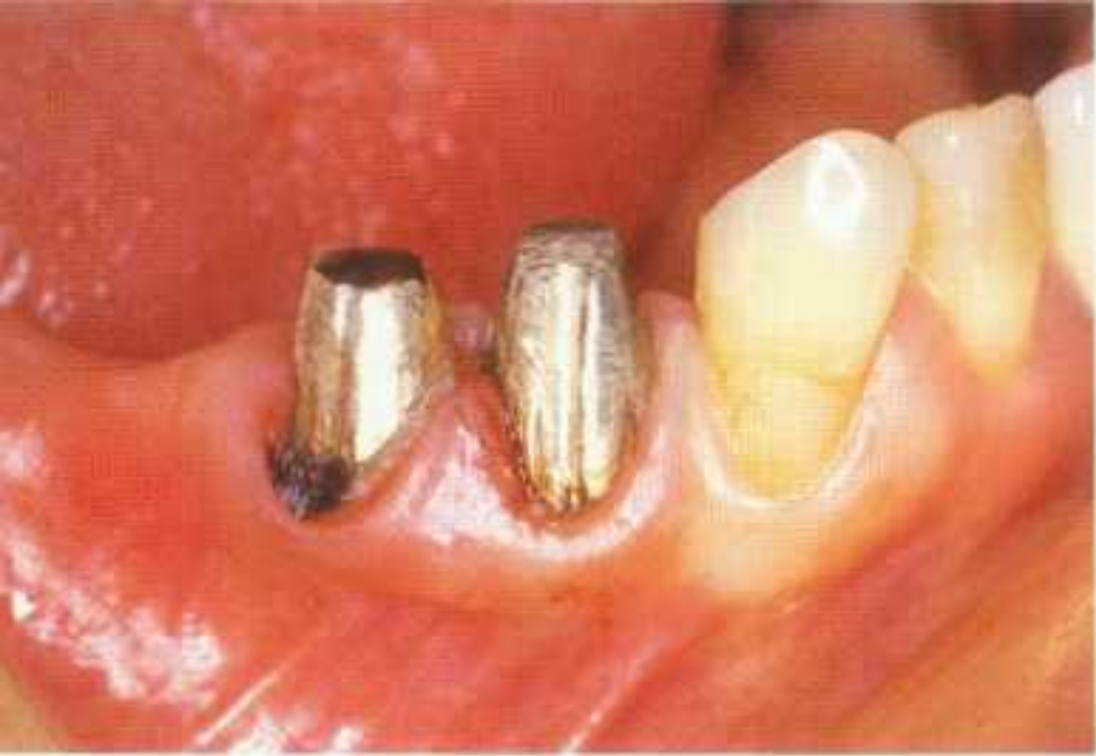1- In sites where there is insufficient gingiva for reduction, the initial incision is placed **intrasulcularly** and a mucoperiosteal flap is raised and apically positioned to gain the needed crown length.

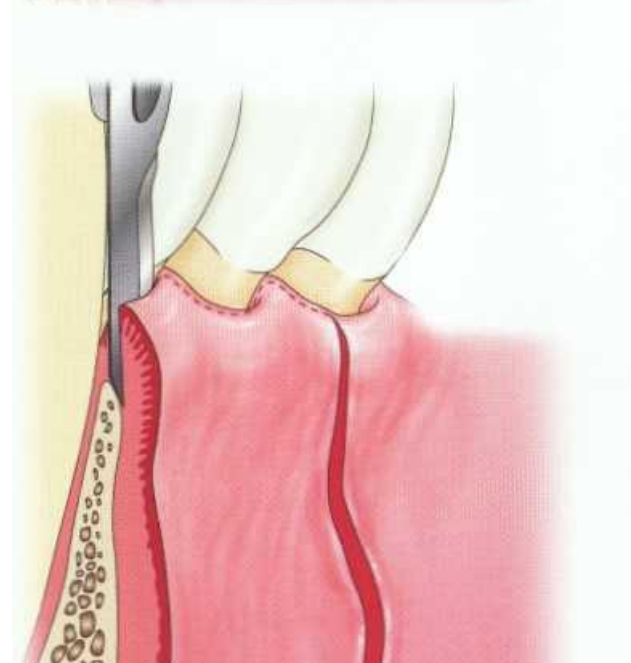
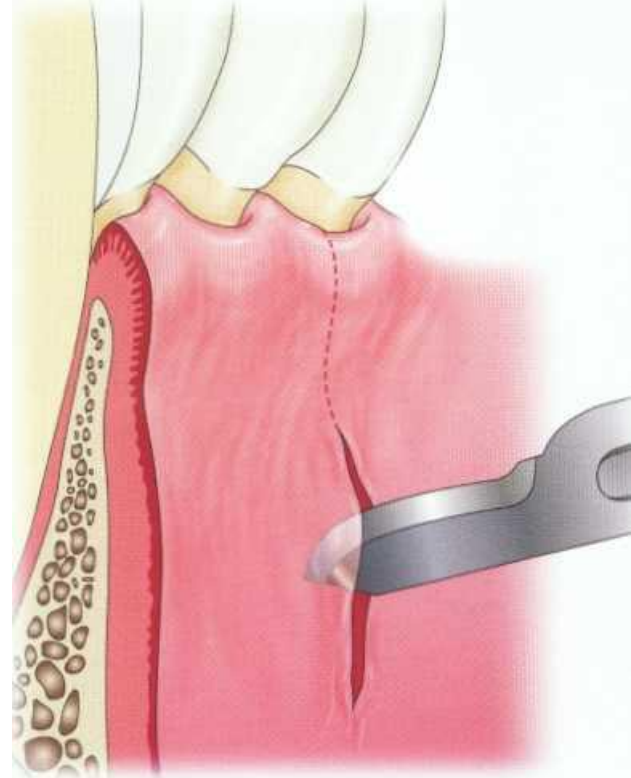
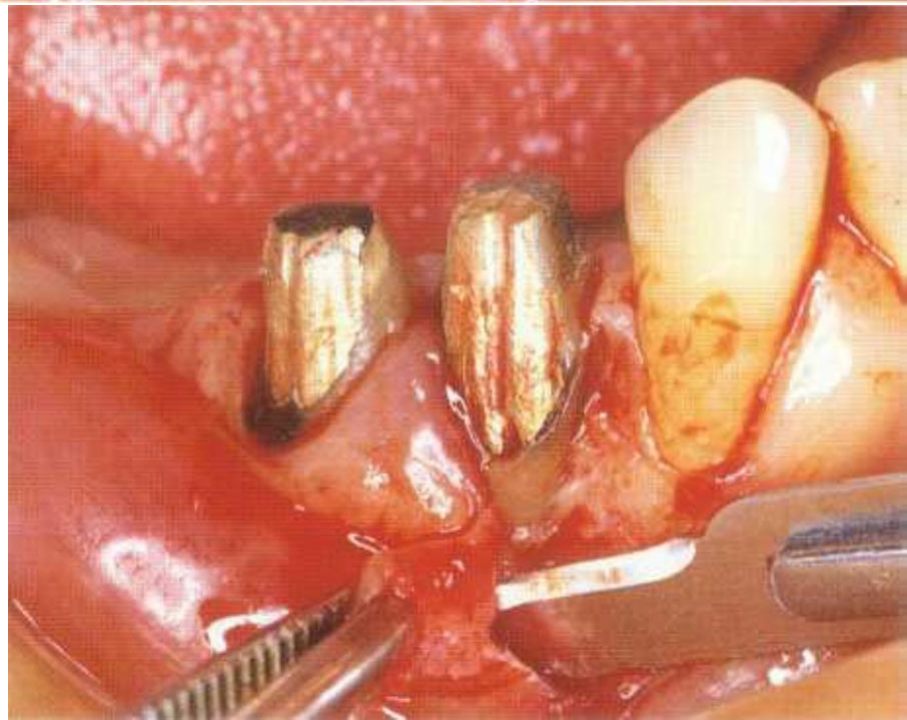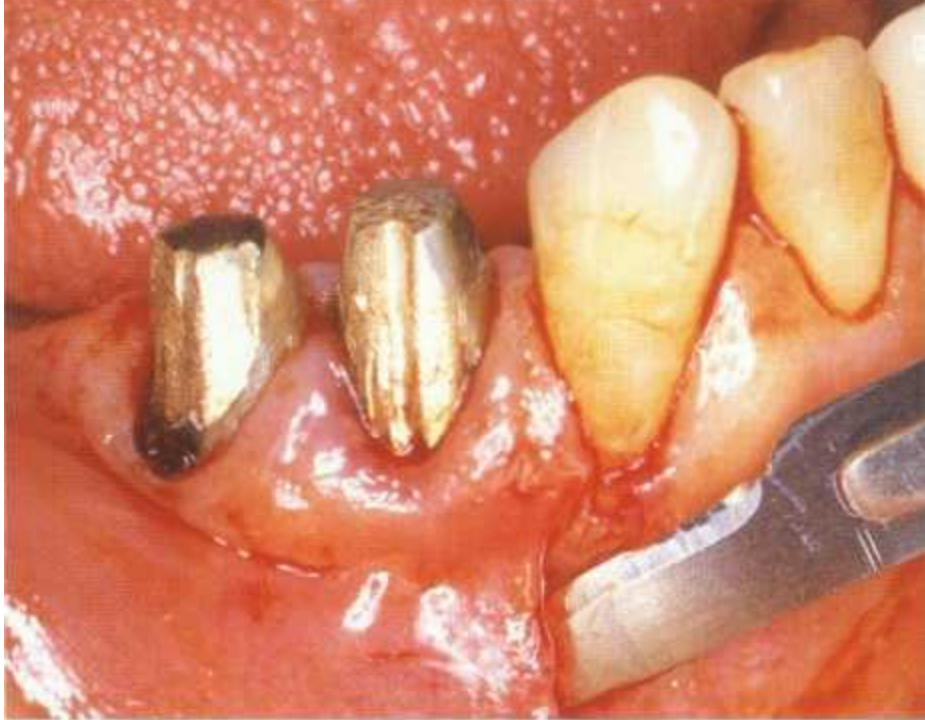2- Crown lengthening of multiple teeth in a quadrant or sextant of the dentition.

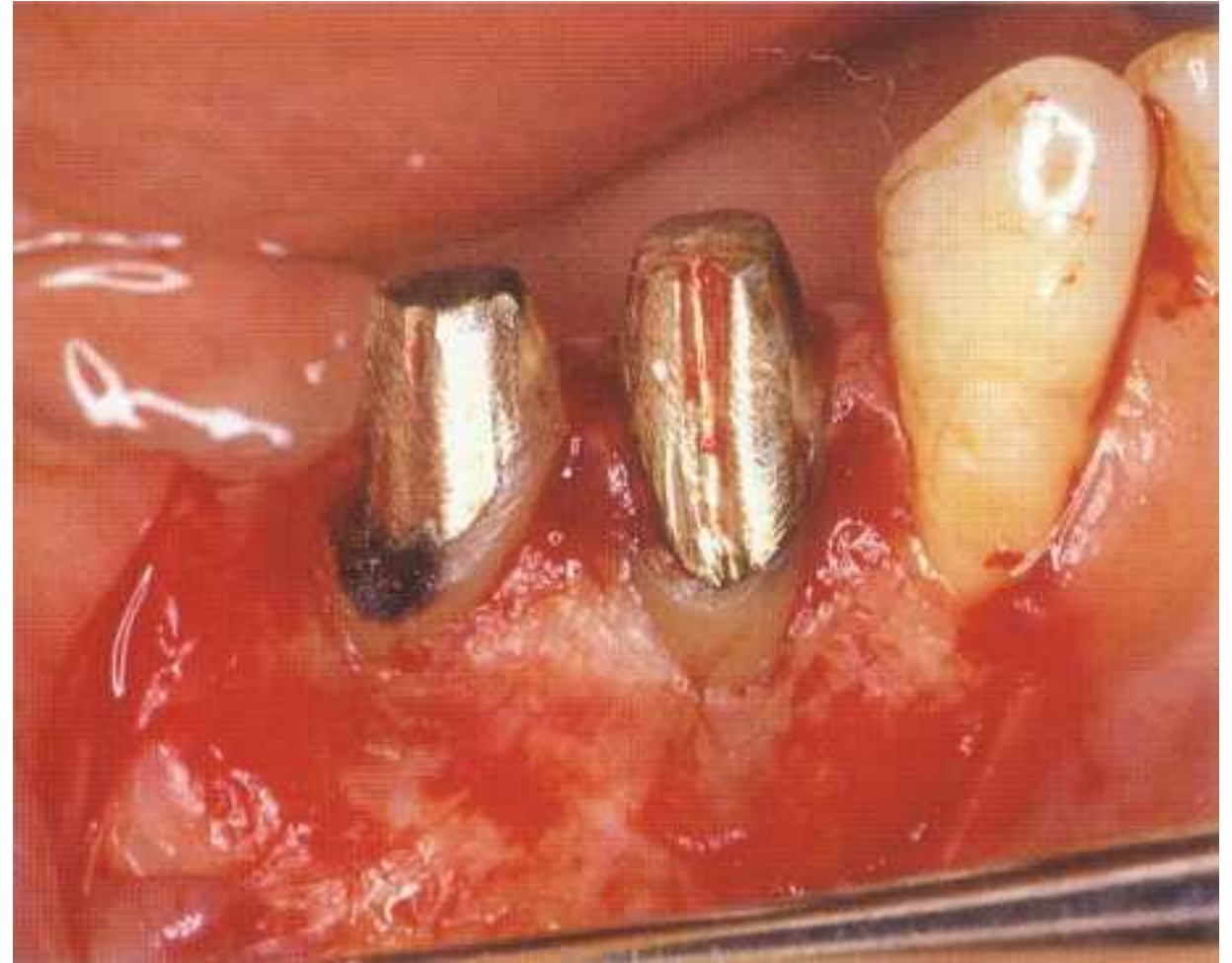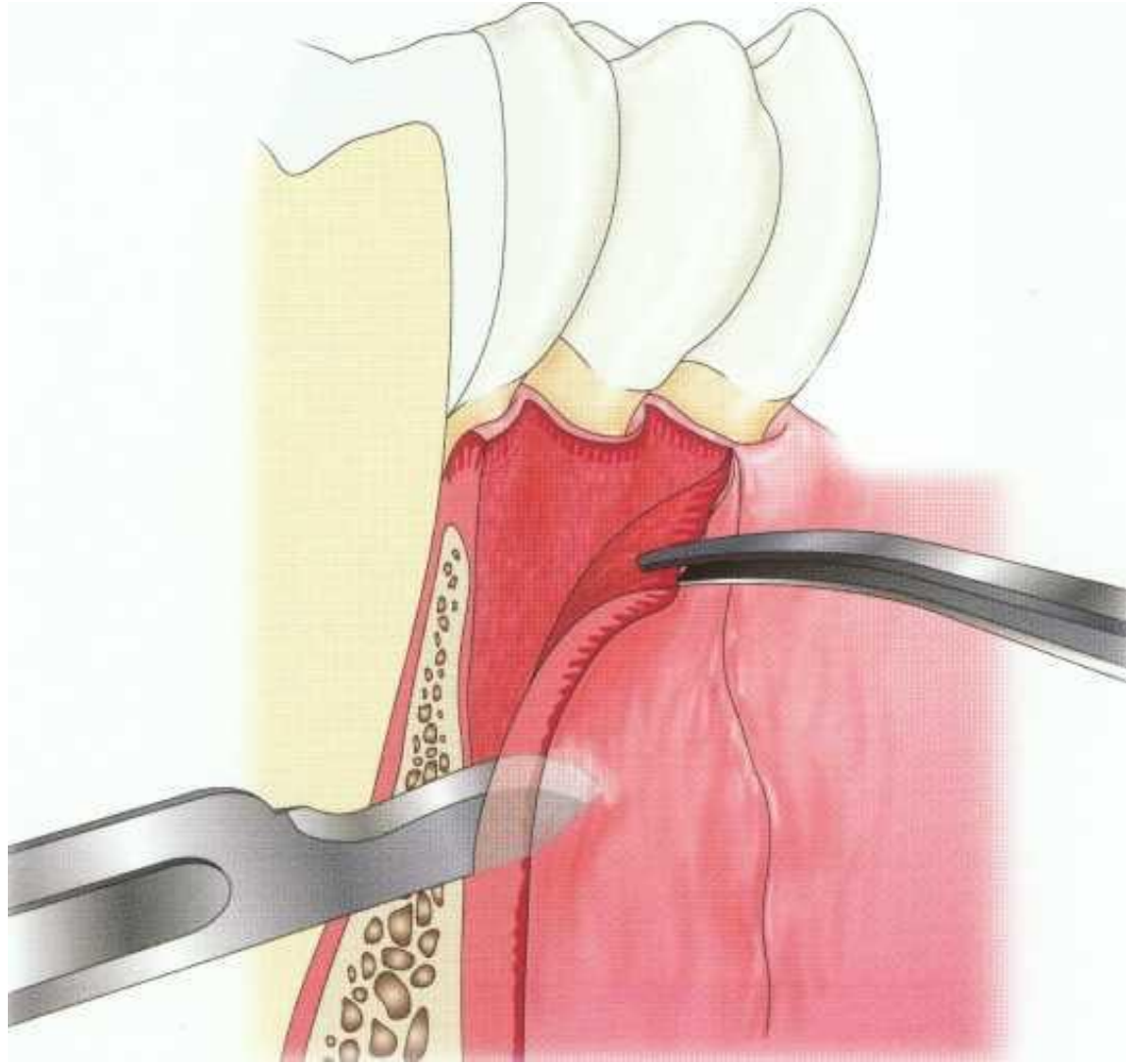
## Contraindication:

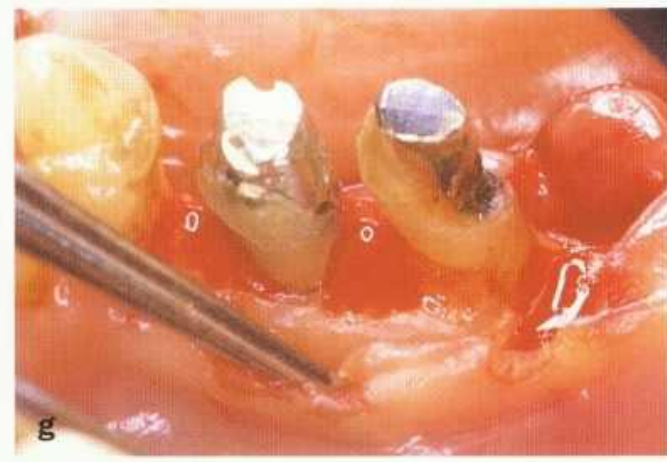
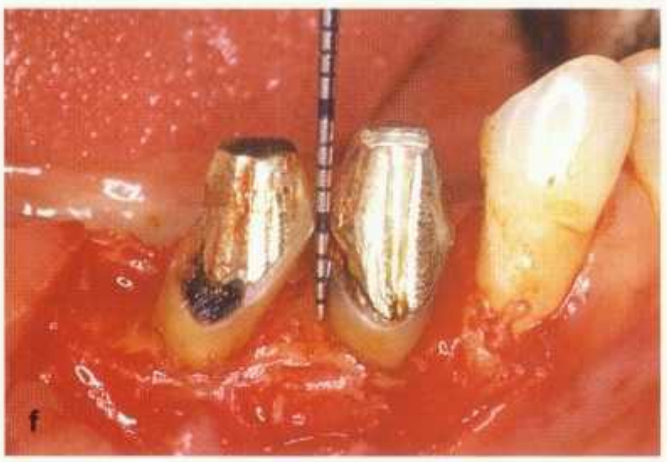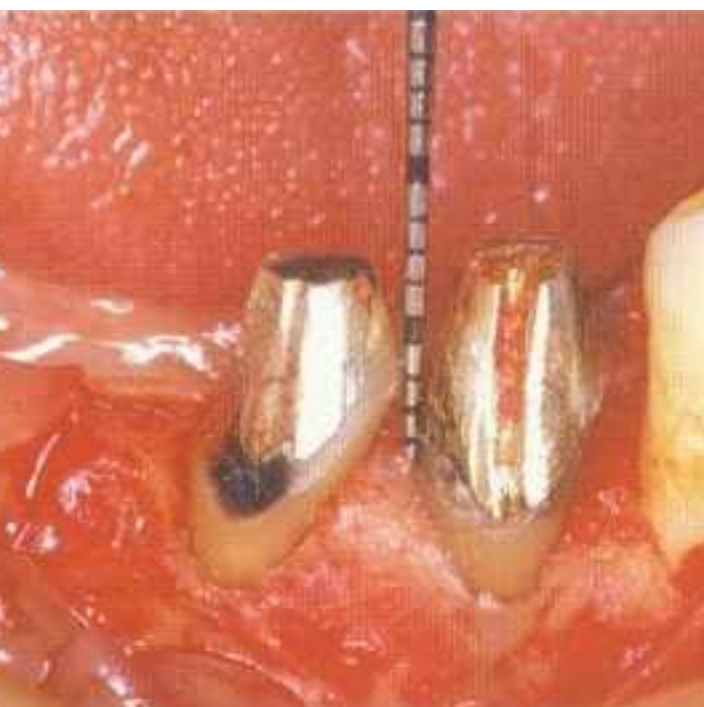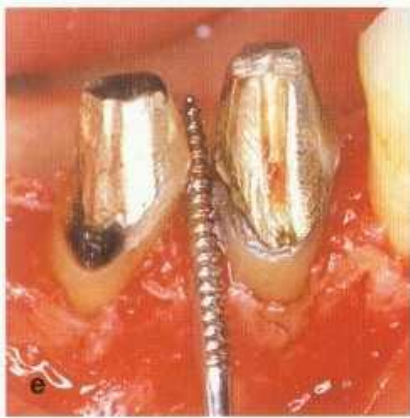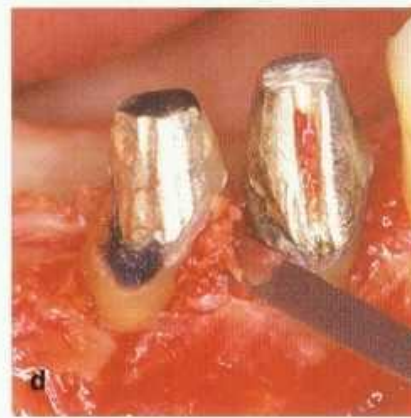
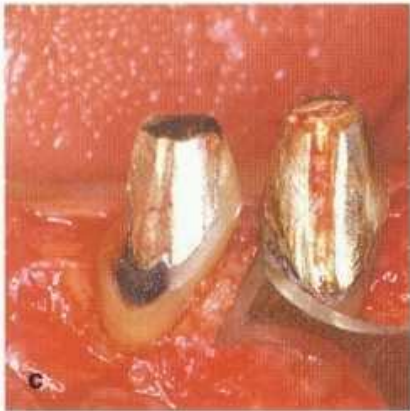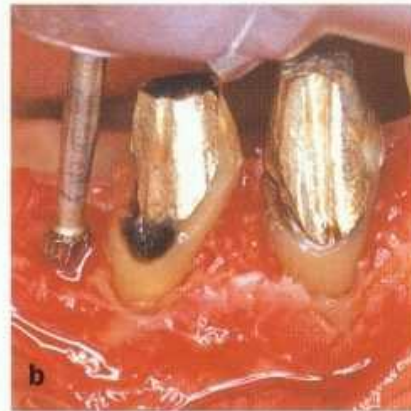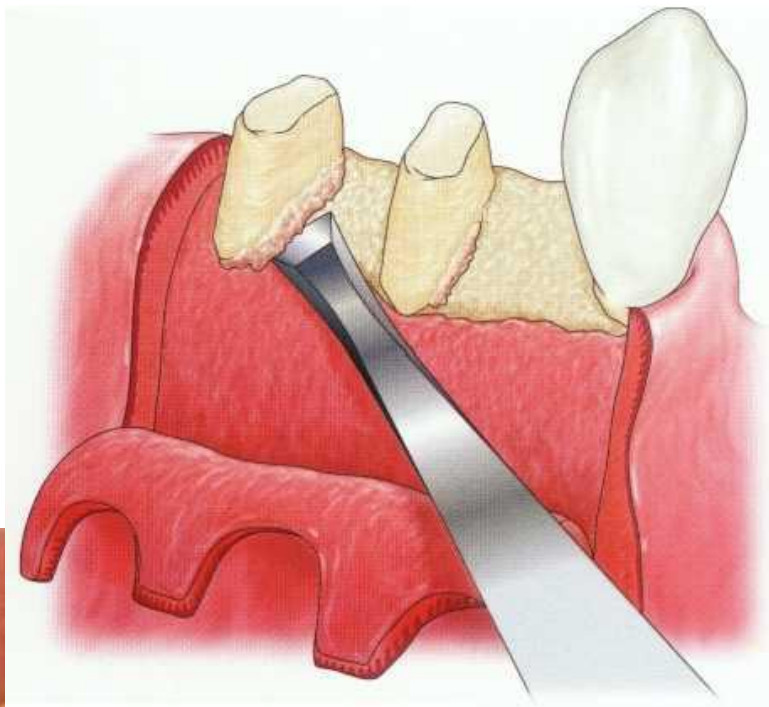
Surgical crown lengthening of **single teeth** in the esthetic

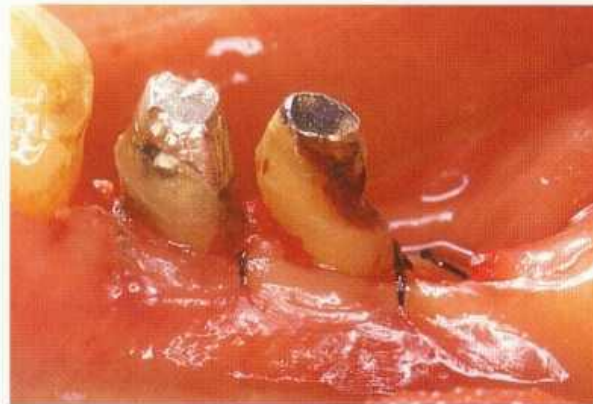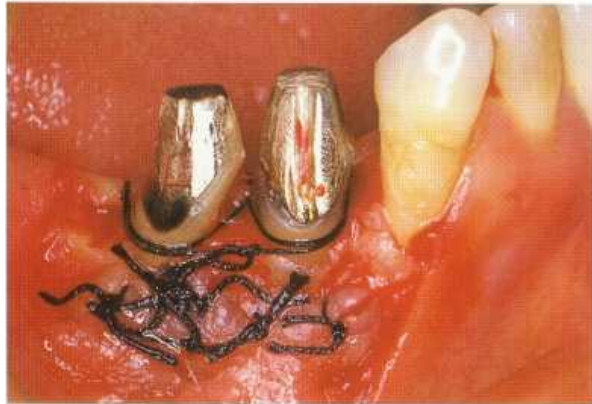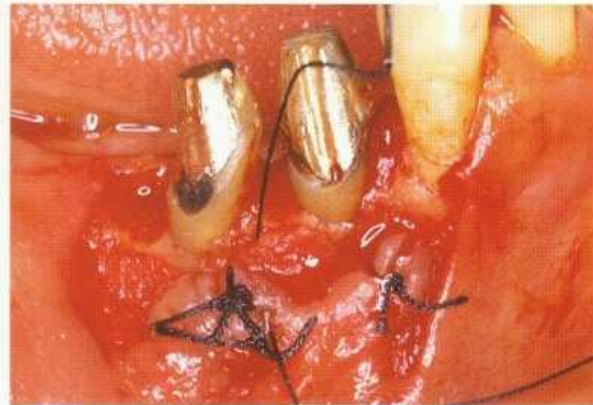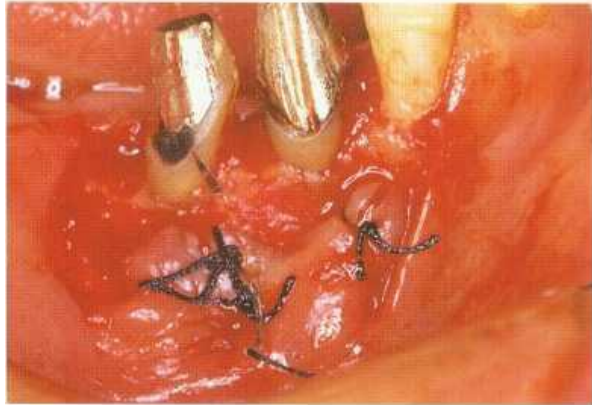
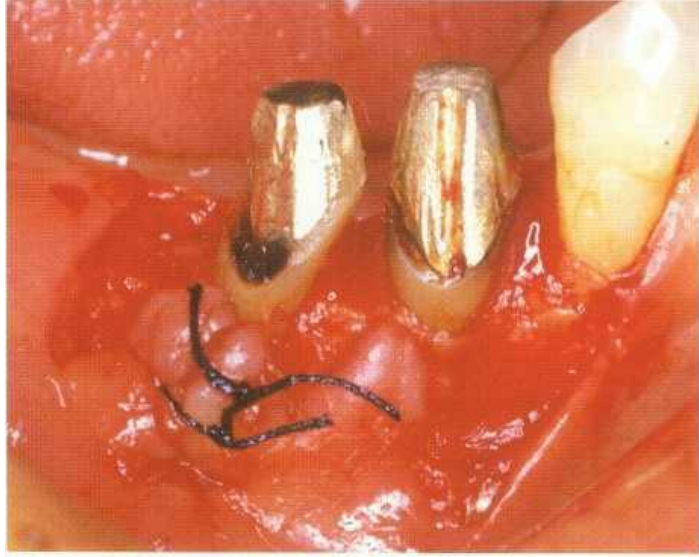Root hypersensitivity , deep infrabony defects, anatomic limitation,

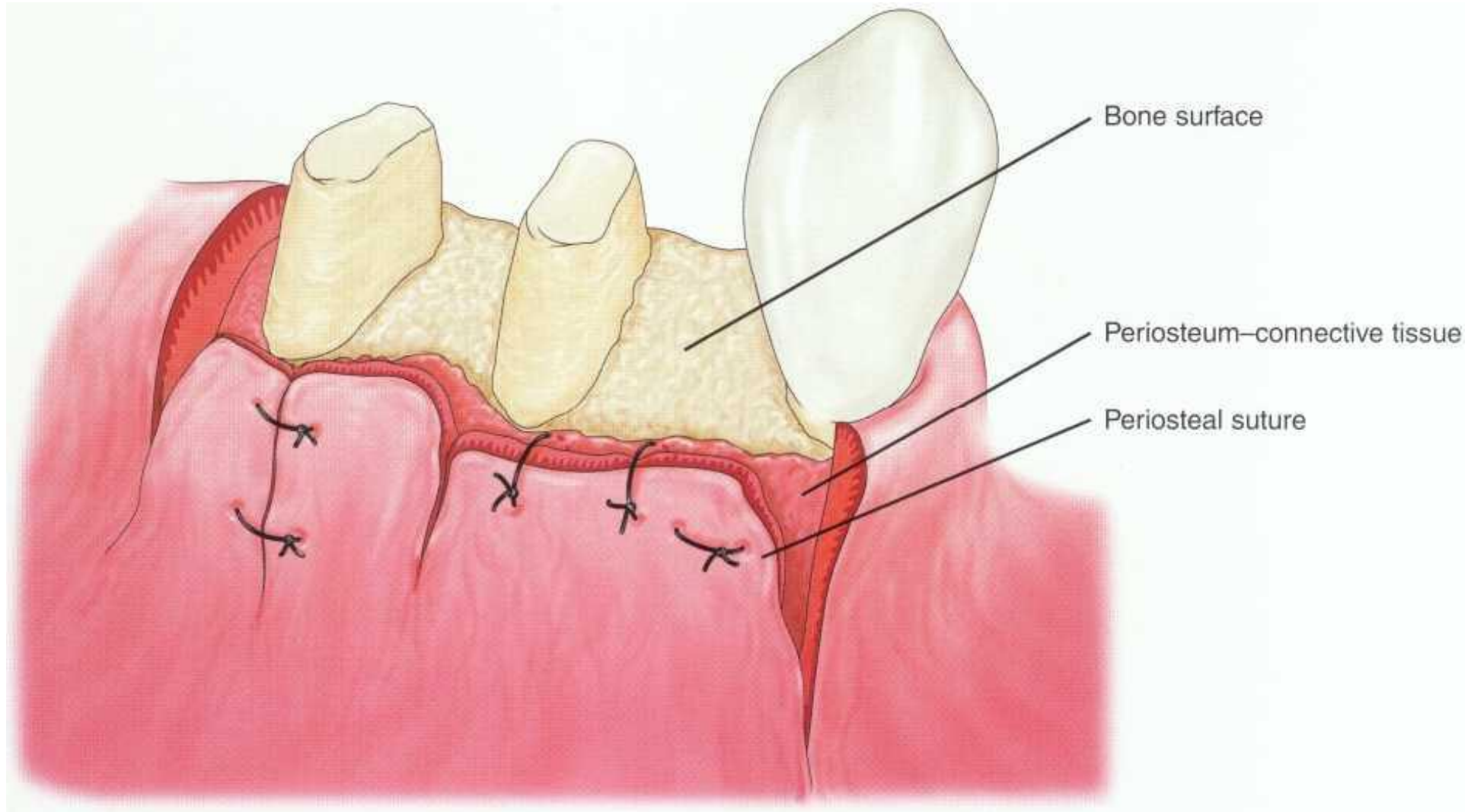


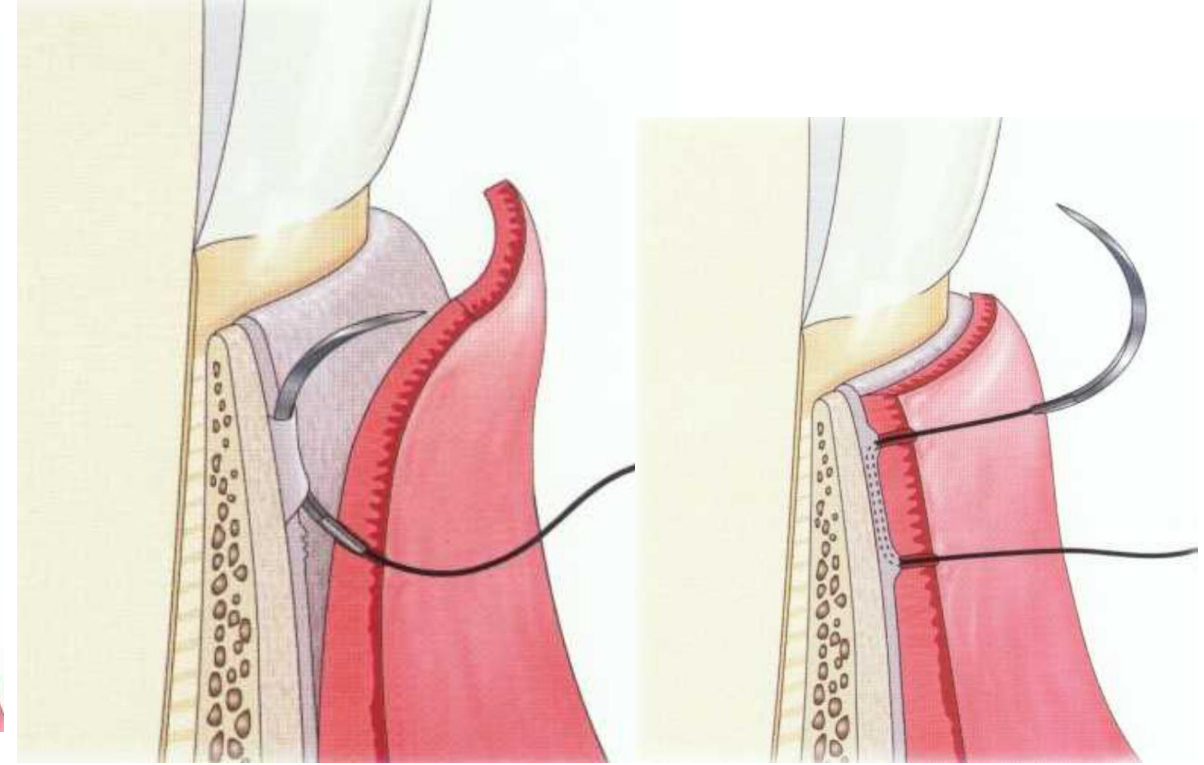
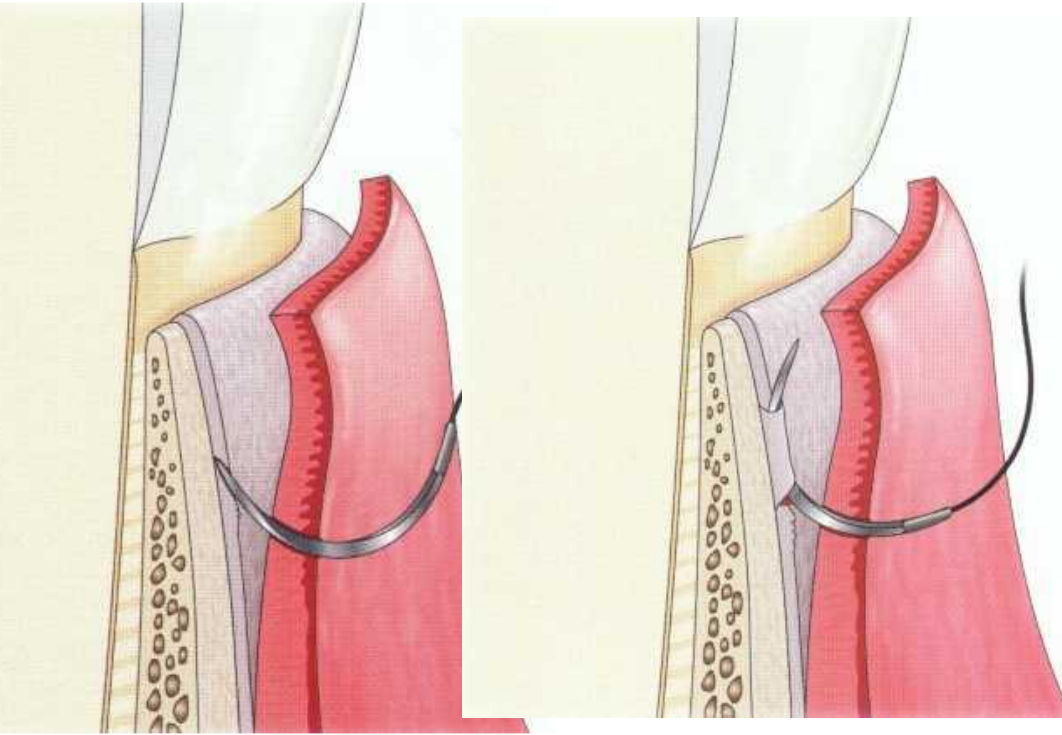




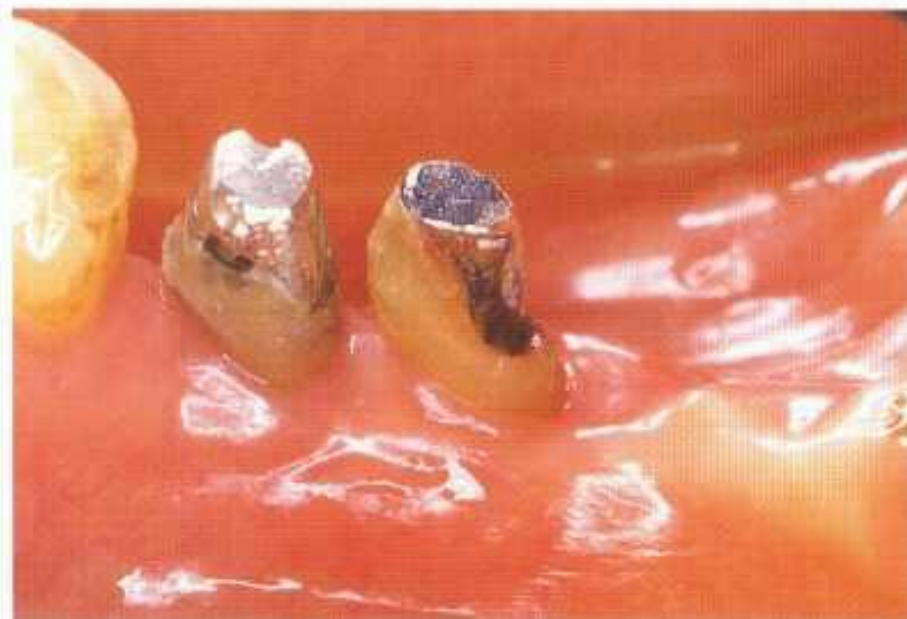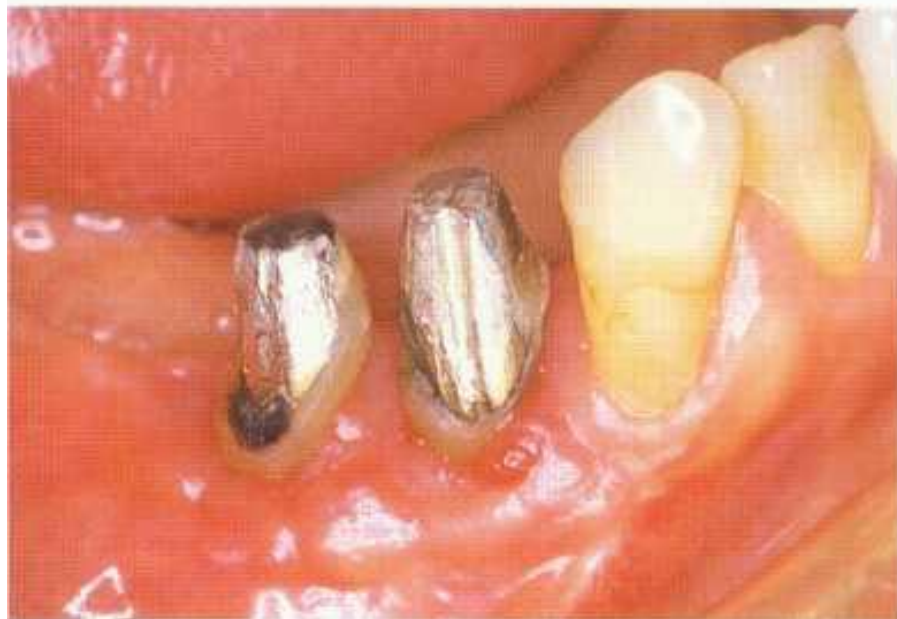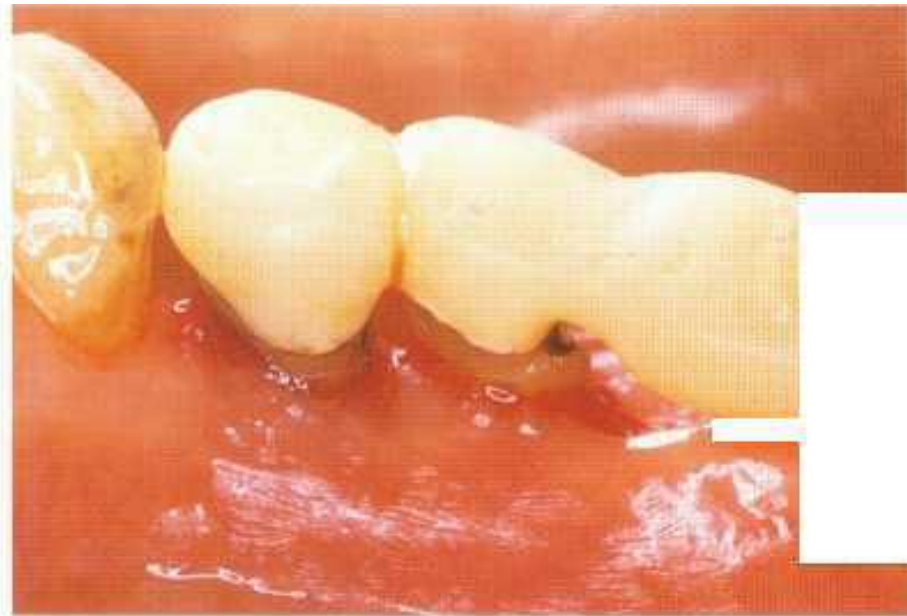


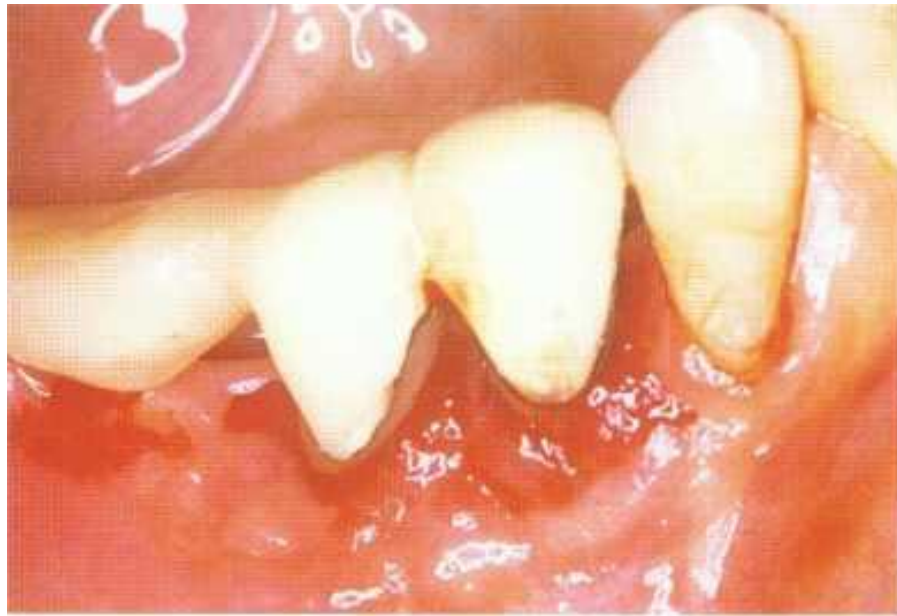


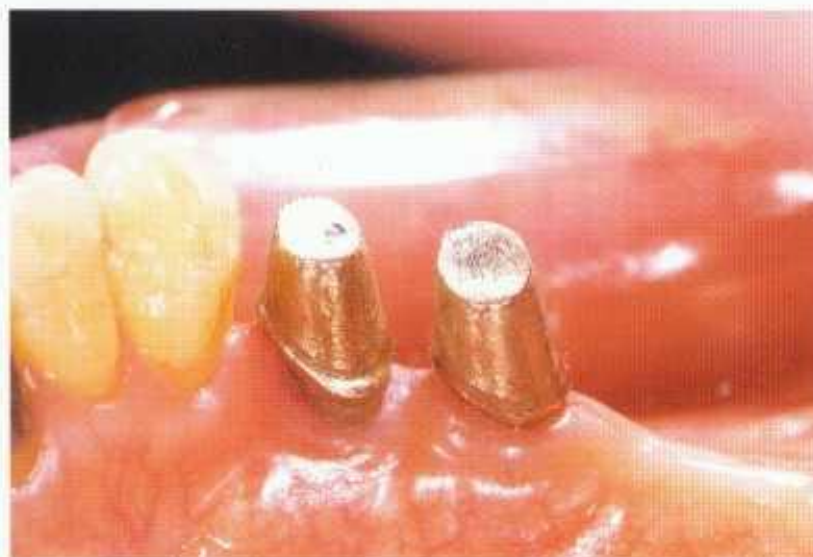
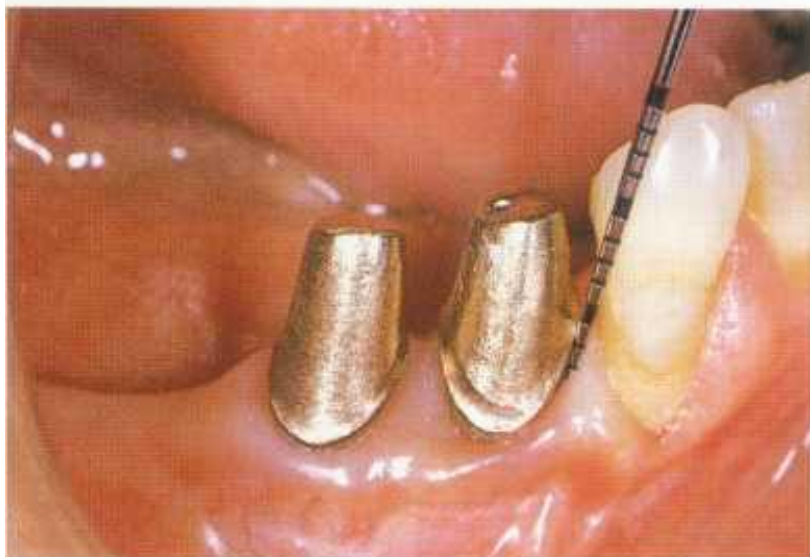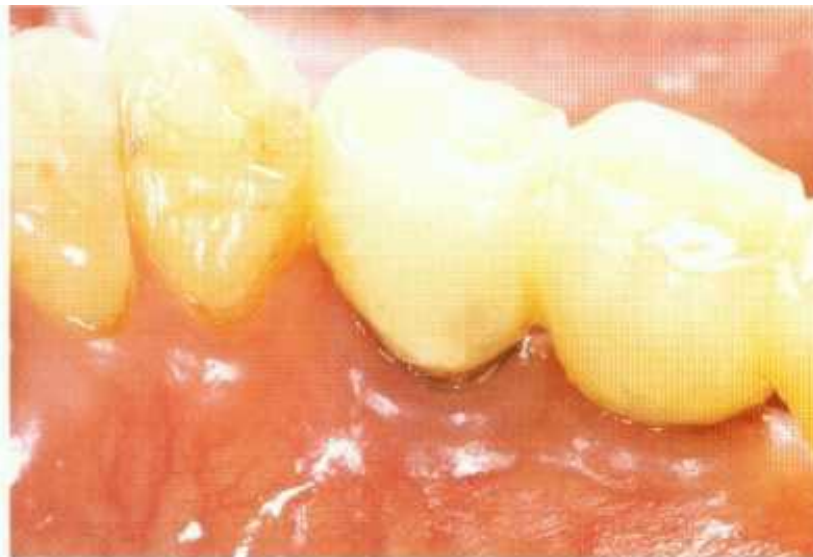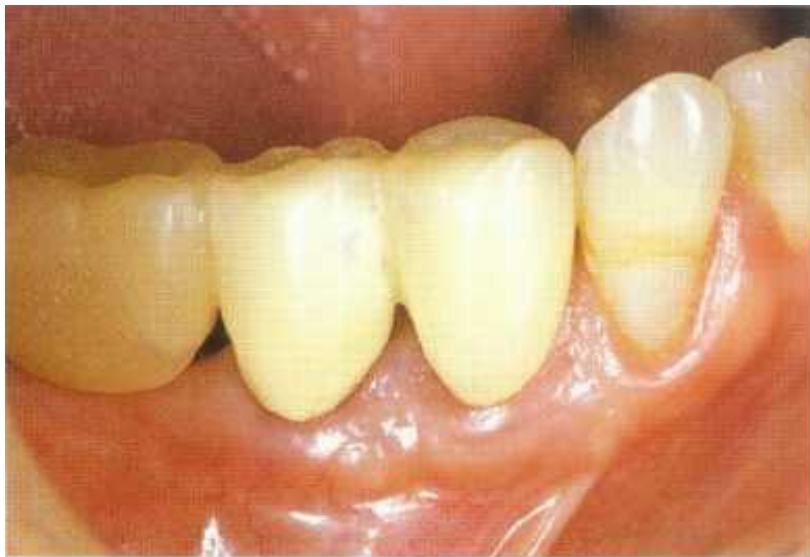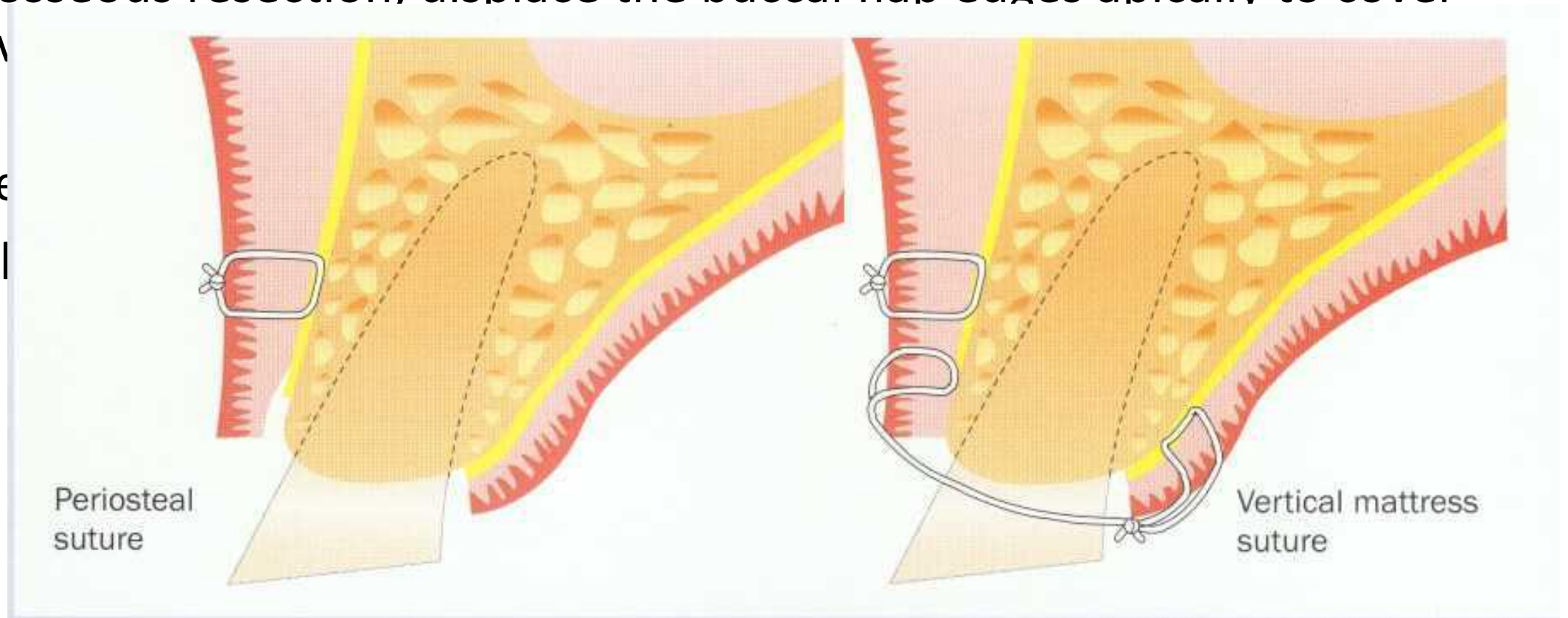








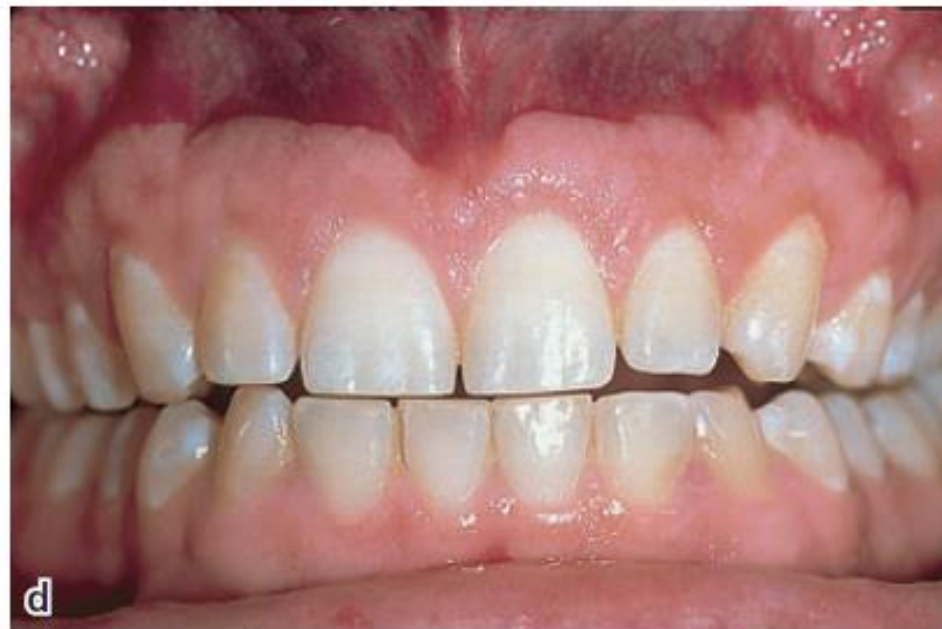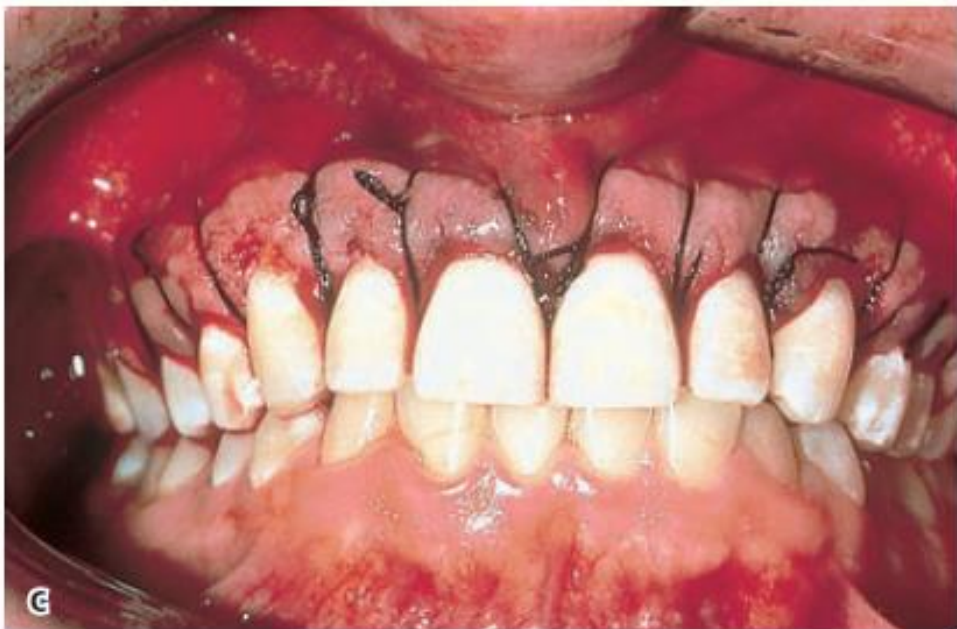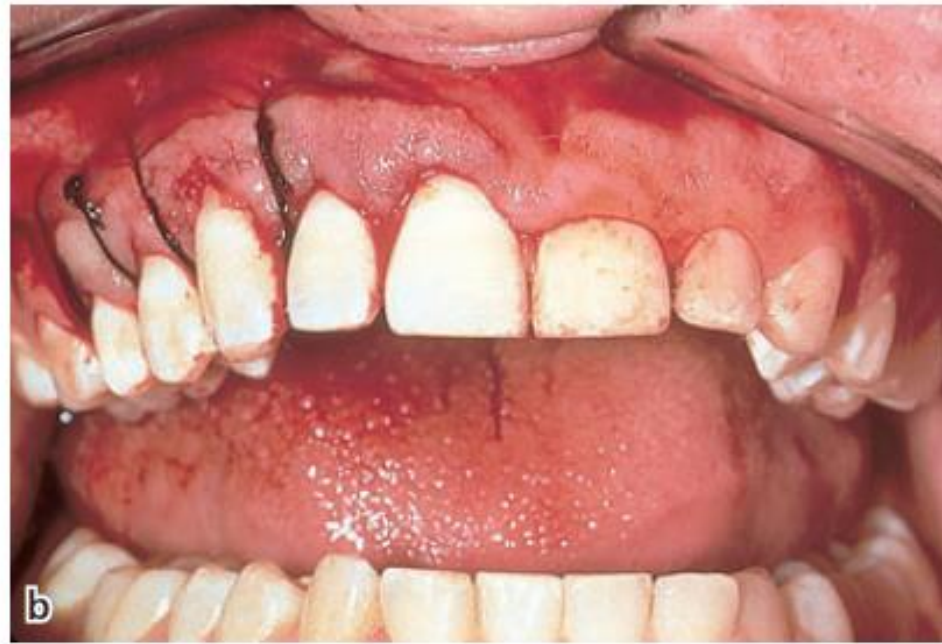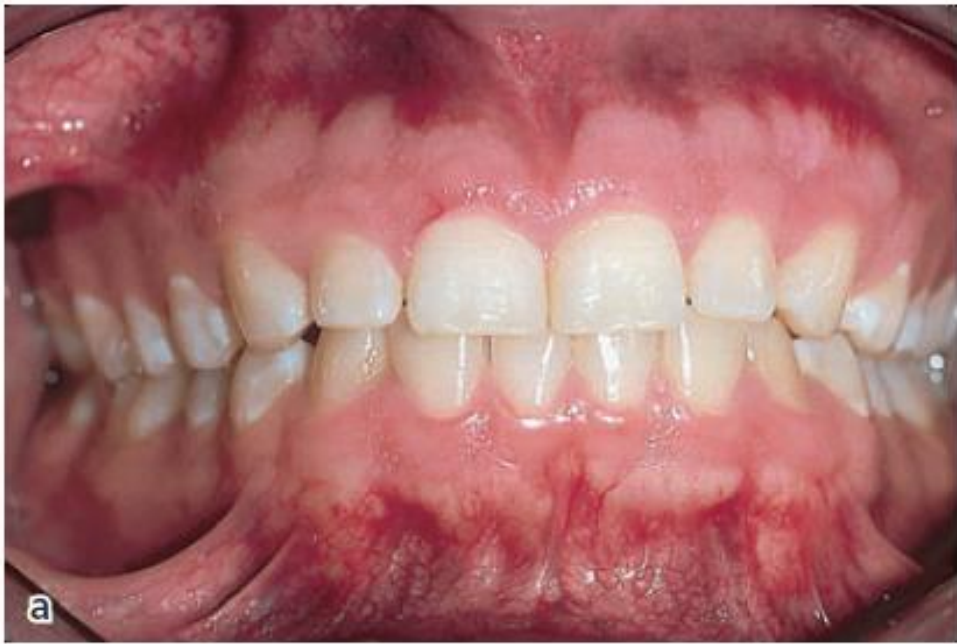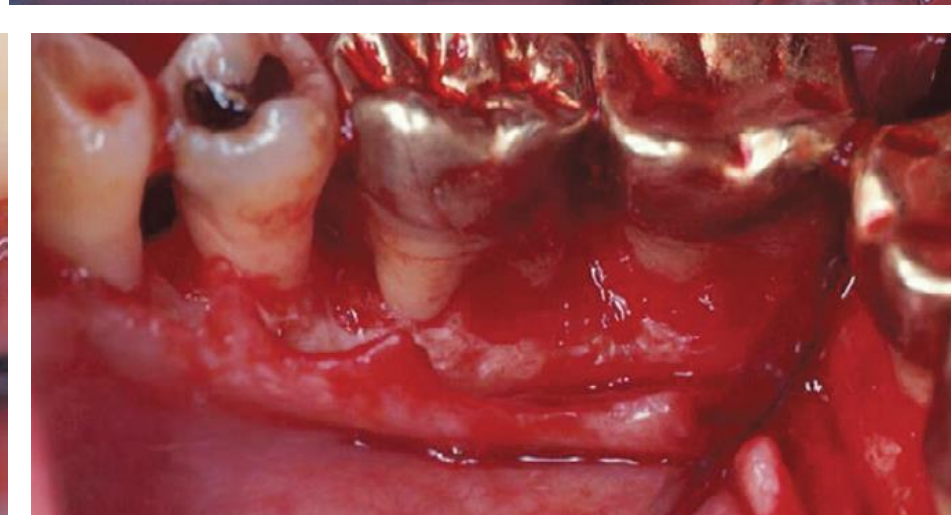
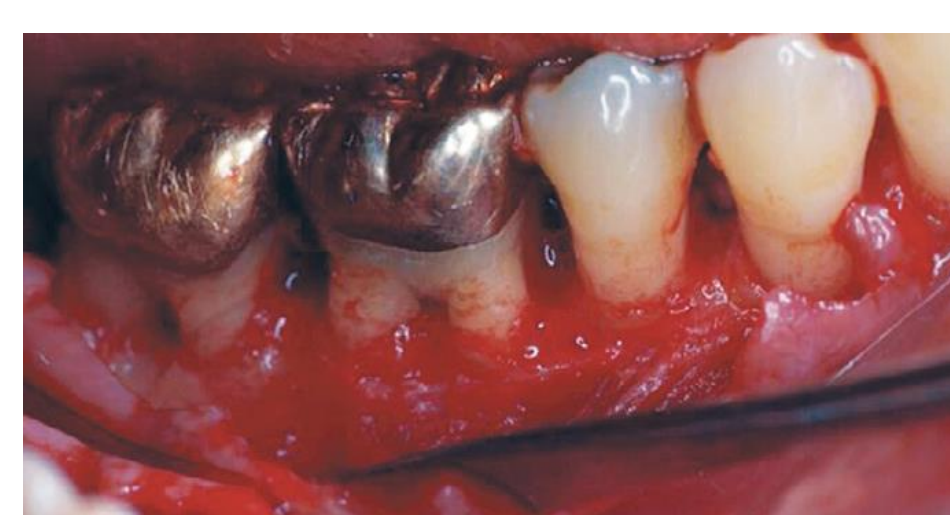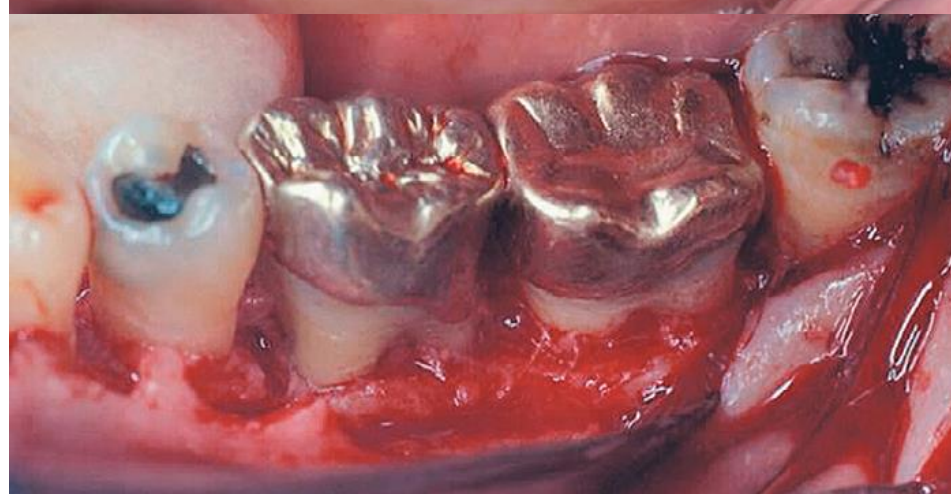
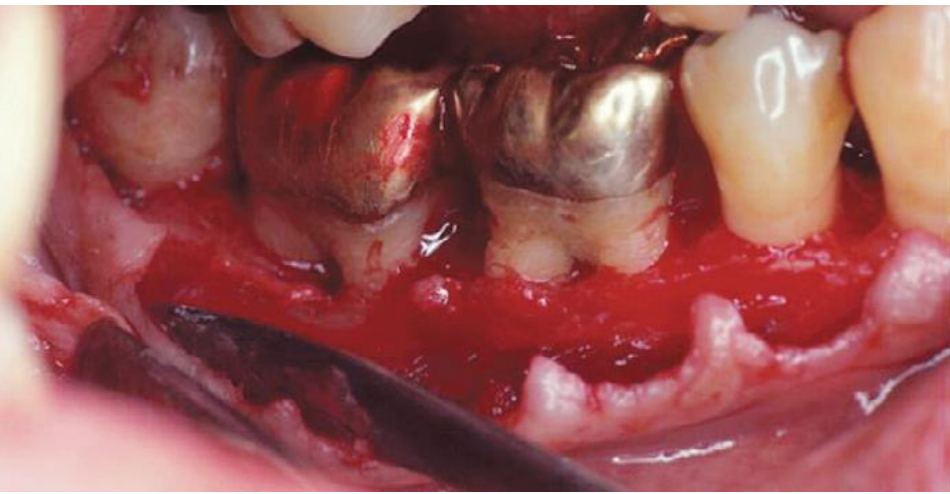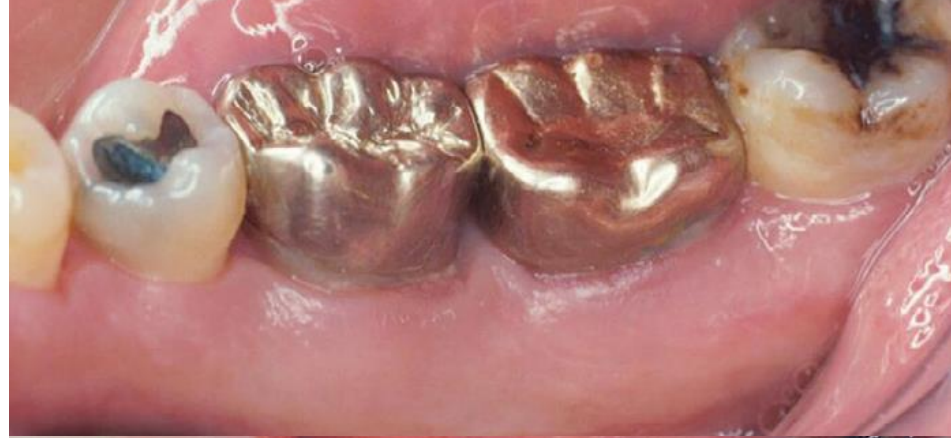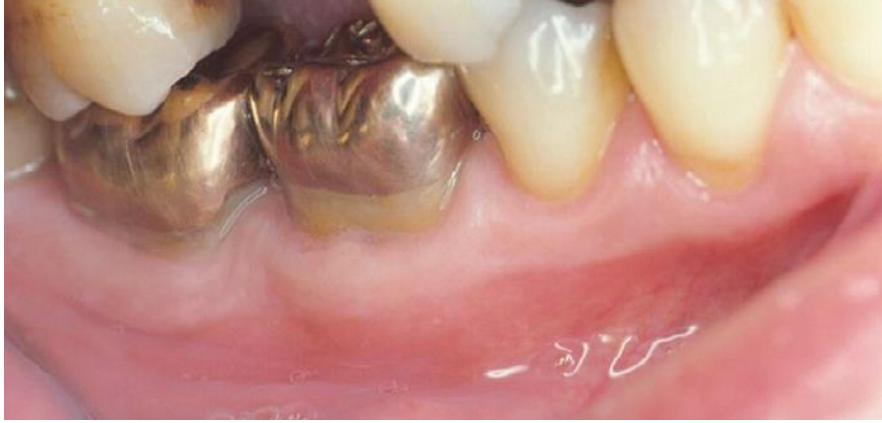After osseous resection, displace the buccal flap edges apically to cover the alveolar ridge. Adapt the buccal flap edges at the alveolar ridge with a vertical mattress suture. Adapt the buccal flap edges at the alveolar ridge with a periosteal suture.

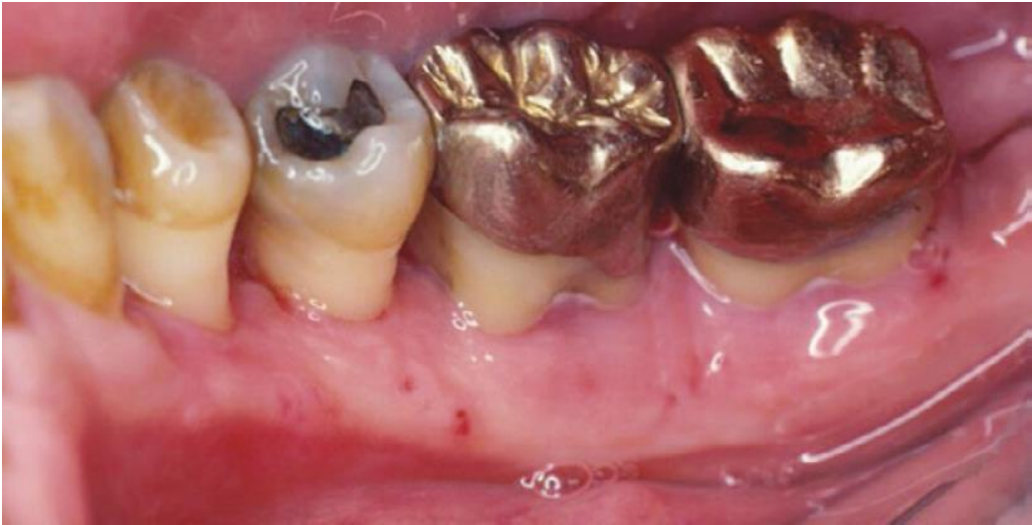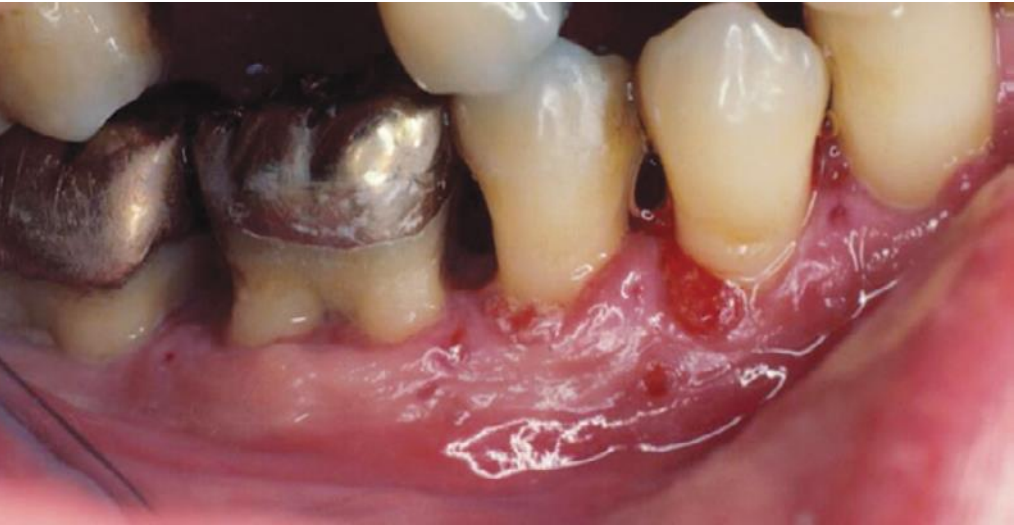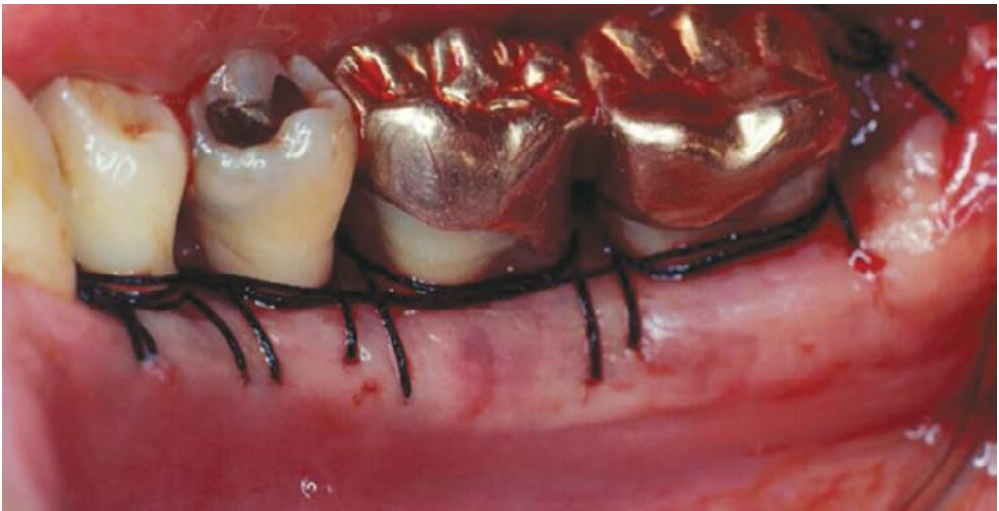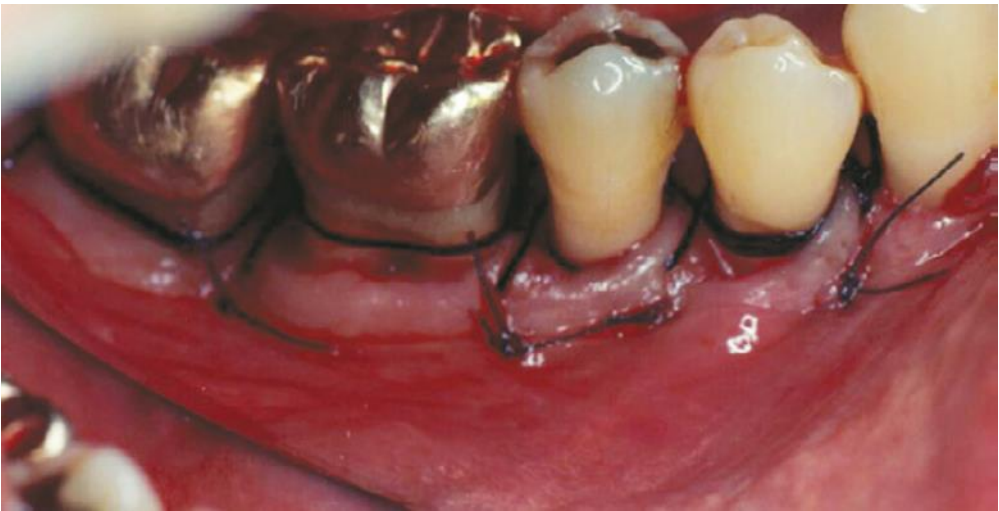




**Fig 44-63** (a) Pretreatment view. The patient, a dentist, requested crown lengthening to lessen his "gummy smile" and give him

# کار انزا





# Wound healing

After the surgical procedure concludes, the healing phase begins. Research has shown that when the clinician creates an apically positioned flap with an osseous resection procedure, the biological width reestablishes itself at an apical level. Researchers have observed that if the margin of the flap is positioned at the level of the osseous crest, a postoperative vertical gain or rebound in supracrestal soft tissues occurs that averages 3 mm.

If the flap margin is placed at a level more coronal to the newly established osseous crest, less vertical gain or rebound in supracrestal soft tissues has been observed

# Healing period

In areas where margins will be supragingival and tissue is reasonably thick, restorative treatment may be performed 2 months postsurgically, though it must be kept in mind that coronal migration of the gingival margin may occur during subsequent months.

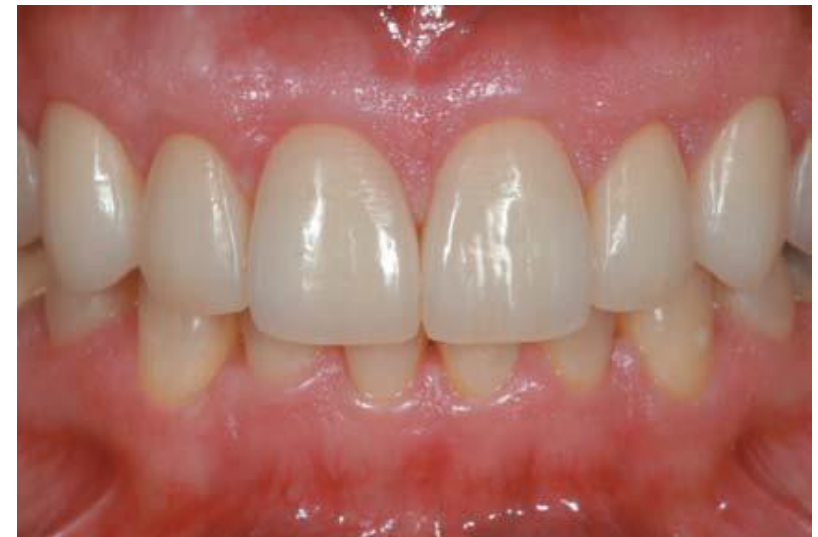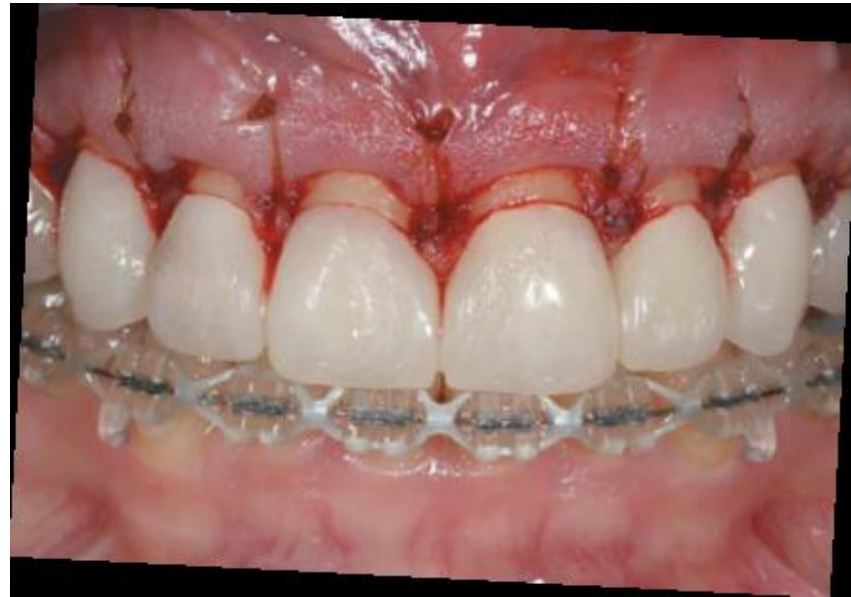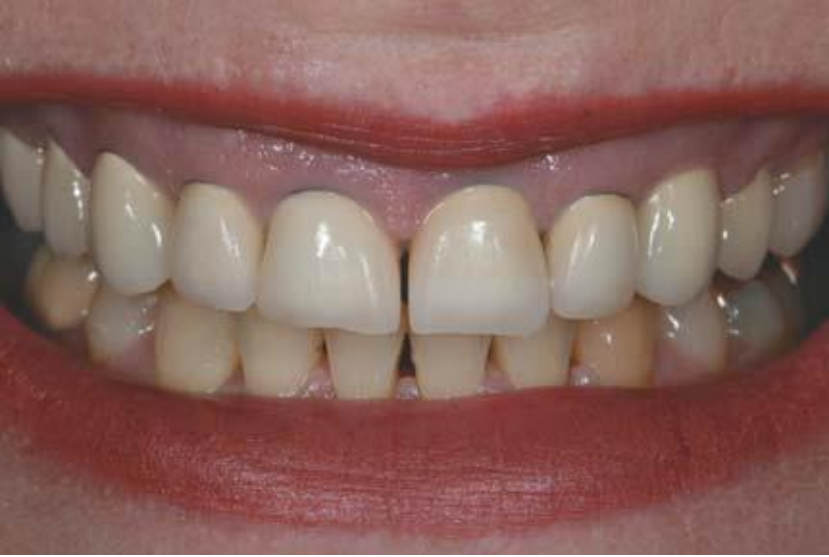In cases with a very thin periodontium it is reasonable to expect some apical migration of the gingival margin during healing.

These changes may also be related to age, with younger patients showing a greater tendency for coronal migration of the gingival margin postsurgically.

In areas where aesthetics is critical, a healing period of at least 6 months is recommended following periodontal surgery



In cases with extremely thin gingival tissue, soft tissue grafting procedures may be used to increase the thickness of keratinized tissue 6 to 8 weeks prior to surgical crown lengthening



# References:

Caranza2019

Clinical Periodontology and Implant Dentistry, Lindhe

Periodontal surgery Sato

Atlas of periodontal surgery Cohen