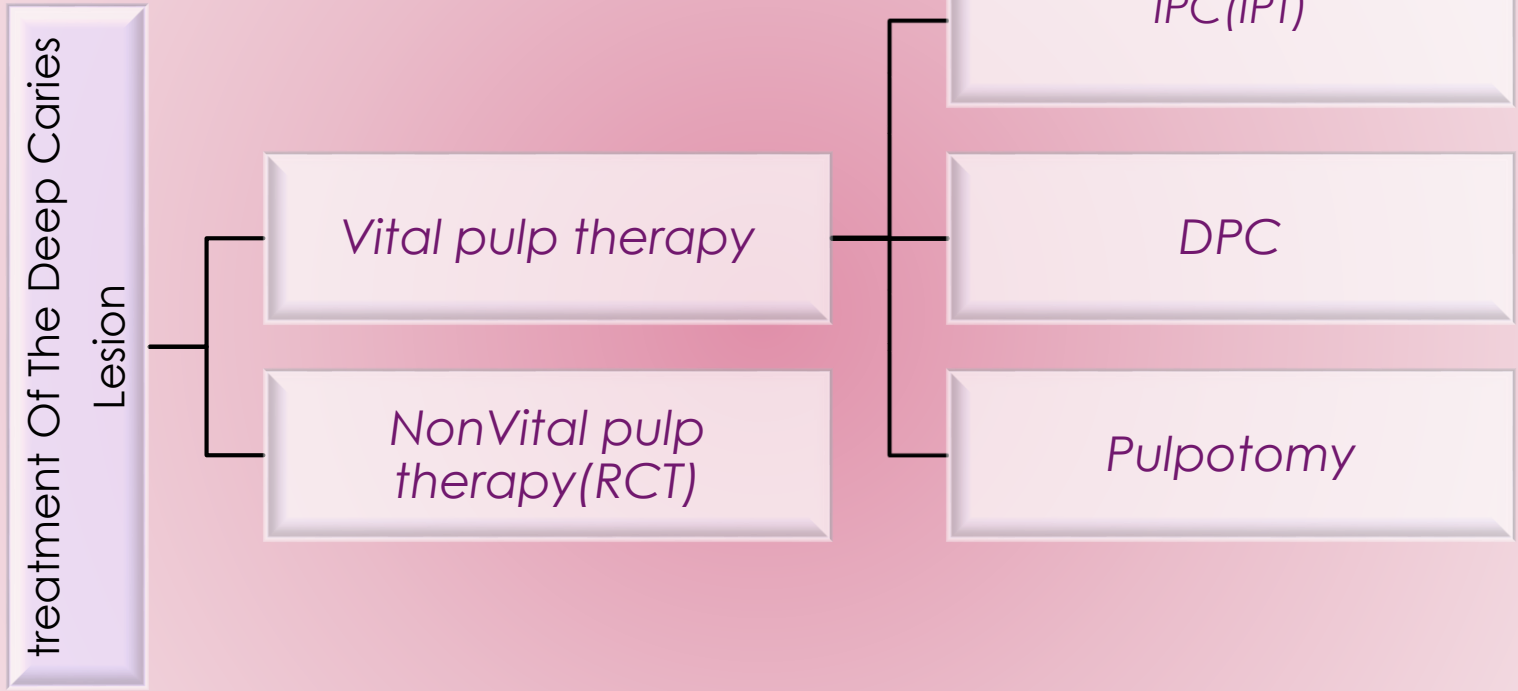


*In The Name Of God*



Vital Pulp Therapy for Primary  
Dentition


Dr Mahboube Daneshvar



Pulpectomy

P.A. DeGroot 75  
dmd, msc

**Figure 19-17** Pulp therapy progression.

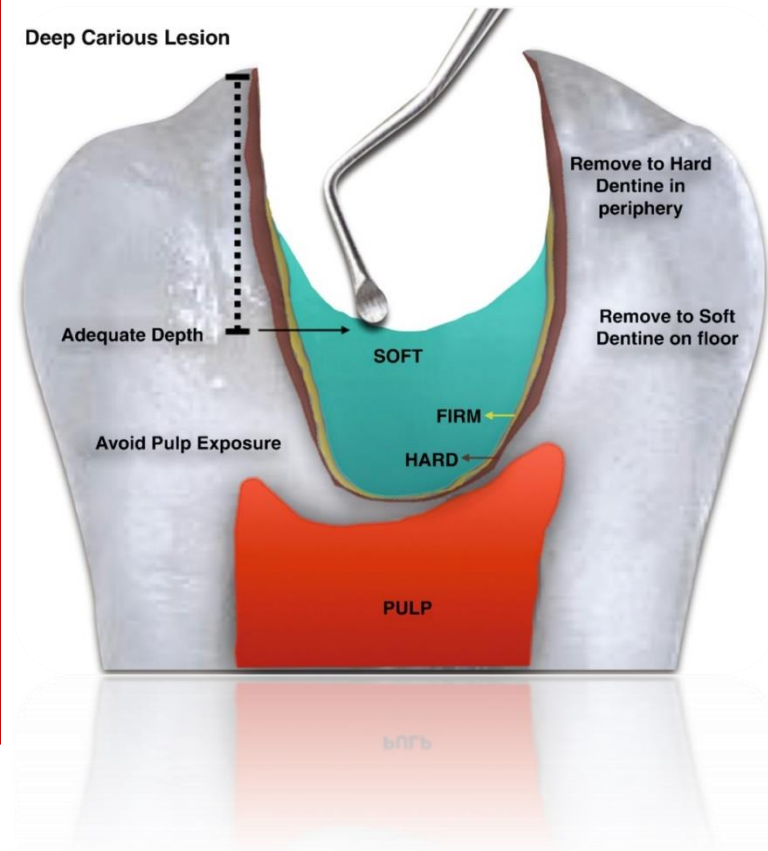


*infected*

*affected dentin*

# different status of dentin

- ❖ *Soft dentin*
- ❖ Leathart Dentin
- ❖ firm Dentin
- ❖ Hard Dentin: (Cri-Dentinaire)



# remove carious tissue

- ✓ **Nonselective removal to hard dentin (complete excavation or complete caries removal)** : overtreatment and is no longer advocated (ICCC).
- ✓ **Selective removal to firm dentin:** in shallow or moderately cavitated dentinal lesions (radiographically extending less than the pulpal third or quarter of dentin).
- ✓ **Selective removal to soft dentin:** in deep cavitated lesions (radiographically extending into the pulpal third or quarter of dentin).
- ✓ **Stepwise removal:**

# Indirect Pulp Treatment

- ✓ 75% of teeth with deep caries actually have clinical pulp exposures.
- ✓ 90% of asymptomatic teeth with deep caries can be successfully treated by IPC.
- ✓ **Indication:**
- ✓ Teeth with deep caries that are free of symptoms of painful pulpitis
- ✓ removing the gross caries but allowing sufficient caries to remain over the pulp horn to avoid exposure of the pulp.
- ✓ The walls of the cavity are extended to sound tooth structure to prevent microleakage
- ✓ Large round bur no.6 or 8
- ✓ Spoon excavator

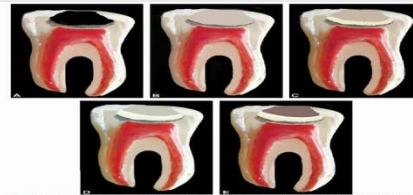


Figure 10-10. (A) Initial state. (B) Removal of gross caries. (C) Extension of cavity walls. (D) Placement of protective restorative material. (E) Final state.

# IPC

- ✓ Arresting the carious process
- ✓ Promoting dentin sclerosis
- ✓ Stimulating the formation of tertiary dentin
- ✓ Remineralizing the carious dentin

# IPC

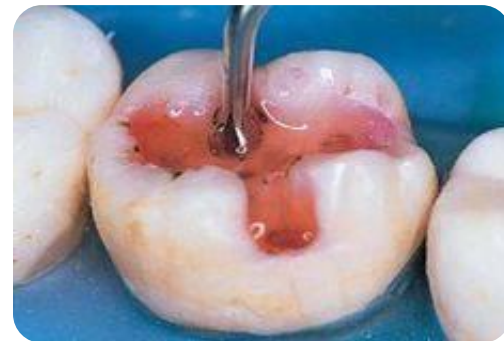- ✓ MTA, CaOH, GI
- ✓ Success rate **more than 90%**
- ✓ Leakage free restoration



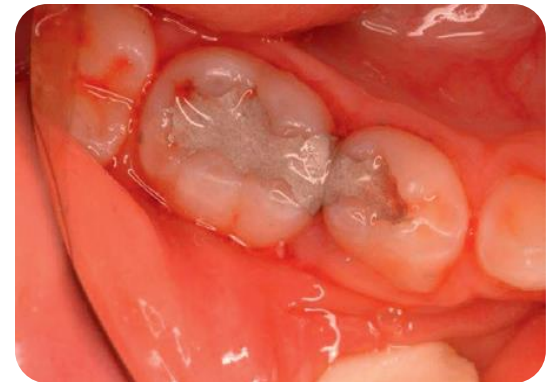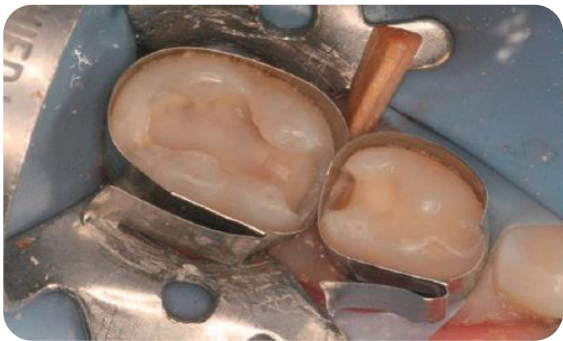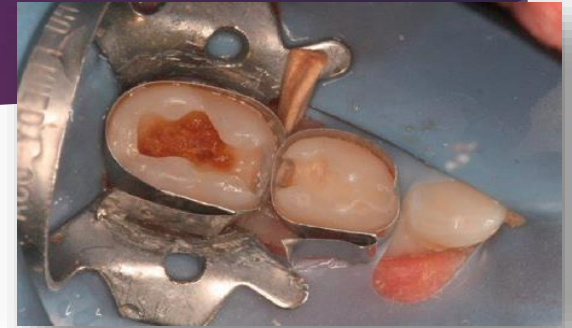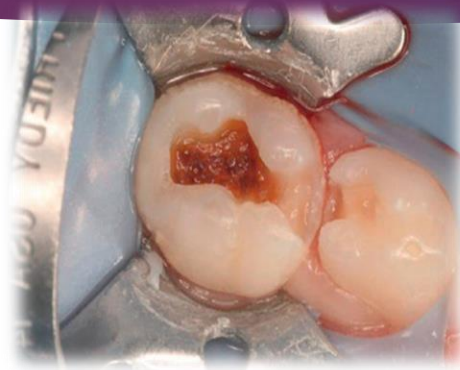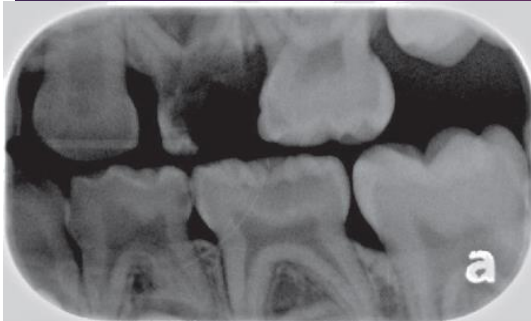


# Carisolv

- A chemomechanical approach to caries excavation
- A gel: three amino acids and a low concentration of sodium hypochlorite
- with specially designed hand instruments.
- sound and carious dentin are clinically separated
- only carious dentin is removed
- a more conservative preparation.
- the time needed to complete the procedure



# IPC



# DPC

▶ Indication:

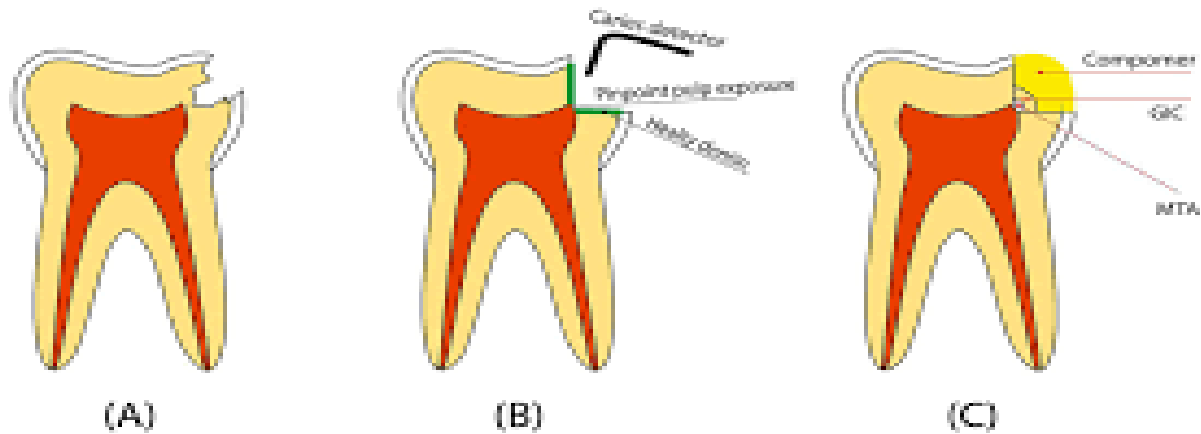
- ✓ healthy pulp has been inadvertently exposed during an operative procedure.
- ✓ The tooth must be asymptomatic,
- ✓ the exposure site must be pinpoint in diameter and free of oral contaminants.
- ▶ with sterile instruments in clean conditions.
- ▶ Use of the rubber dam

# DPC

- ▶ calcium hydroxide medicament
- ✓ to stimulate dentin formation
- ✓ “heal” the wound and maintain
- ✓ vitality of the pulp
- ▶ DPC of a carious pulp exposure in
- ✓ primary tooth :is not recommended
- ✓ immature permanent teeth : can be used with success

# Direct Pulp Capping

## DIRECT PULP CAPPING

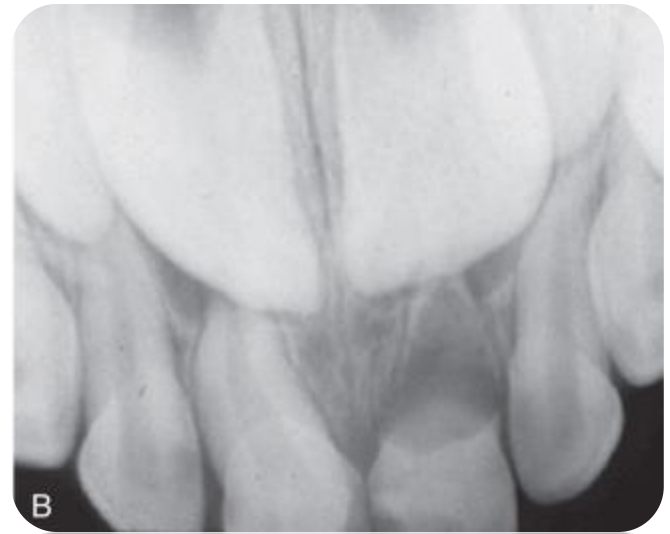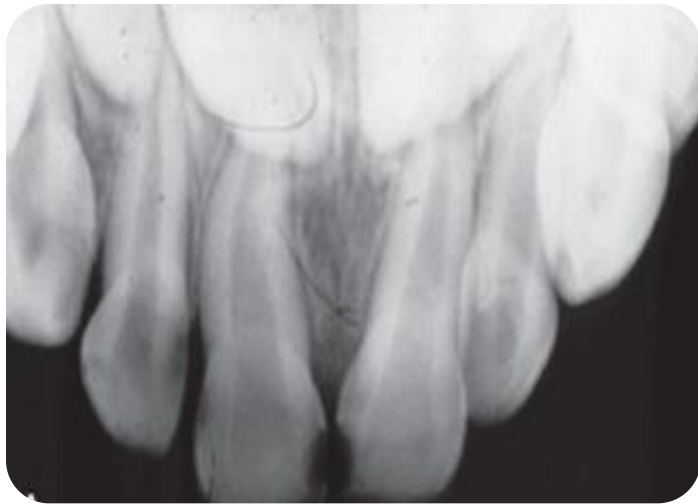


# DPC

## ▶ Failure results

- A. acute dentoalveolar abscess
- B. internal resorption
- ✓ high cellular content of the primary pulp tissue

# Failure results Dpc

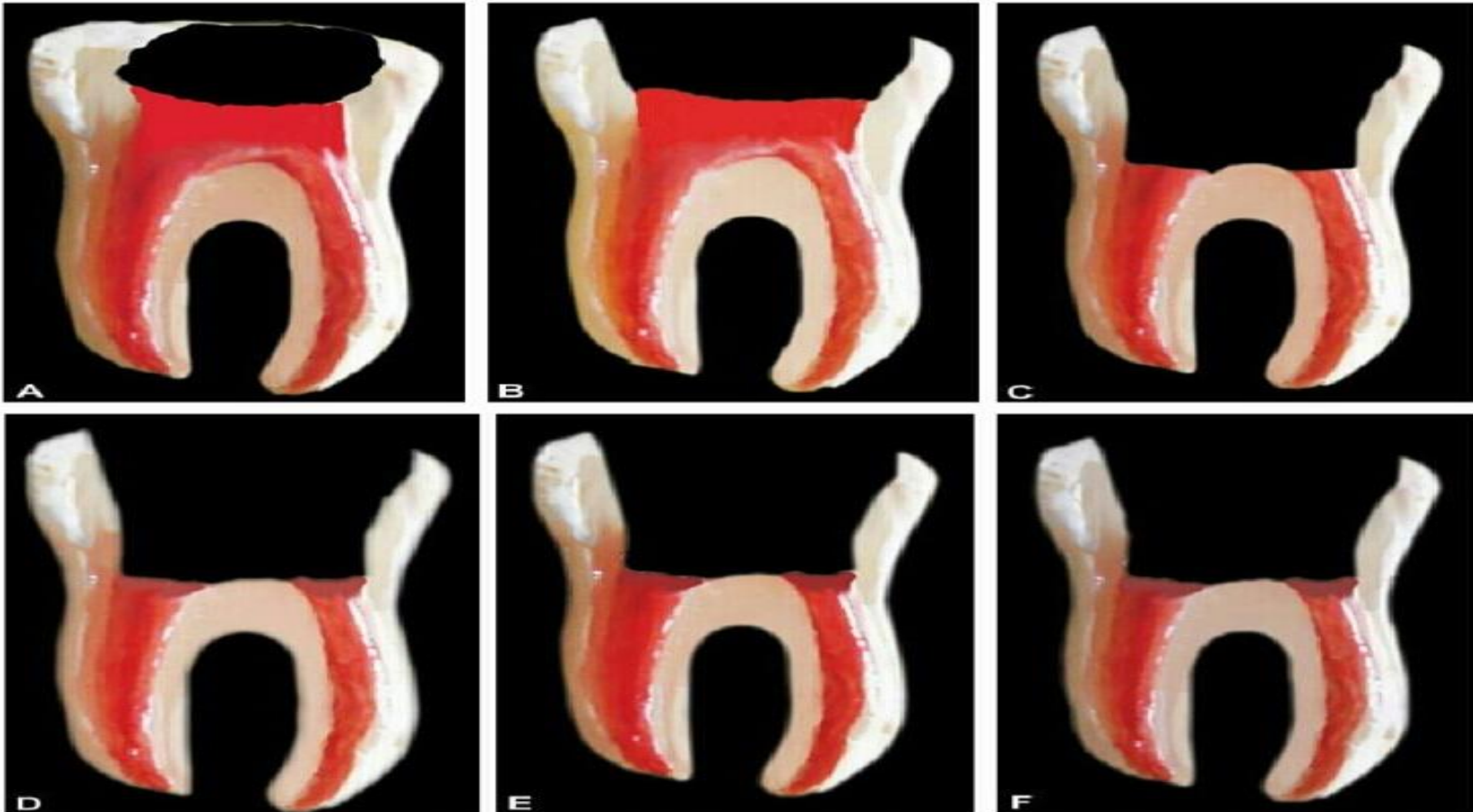




# DPC

- ▶ DPC in primary teeth still be viewed with reservation, only recommended for exposed pulp in older children, 1 or 2 year before normal exfoliation

# Pulpotomy



**Figs 8.14A to F:** Formocresol pulpotomy: (A) Caries extending up to the pulp; (B) Access opening made; (C) Coronal pulp removed; (D) Formocresol pellet placed on the amputated pulp stump for 5 minutes; (E) Zinc oxide eugenol mix is placed over the fixed pulp; (F) Tooth is sealed with amalgam restoration

# Pulpotomy

- Indication:

- ▶ However, when the carious process has reached the pulp or in incidences of direct pulpal exposure during excavation of a carious lesion,
- ▶ radicular pulp tissue is healthy
- ▶ or is capable of healing after surgical amputation of the affected or infected coronal pulp.

# Pulpotomy

## ▶ Contraindications :

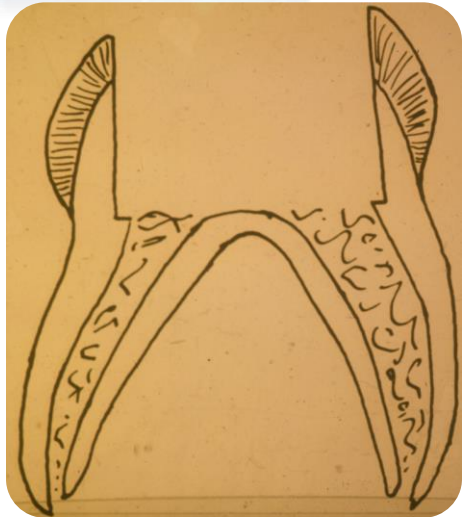
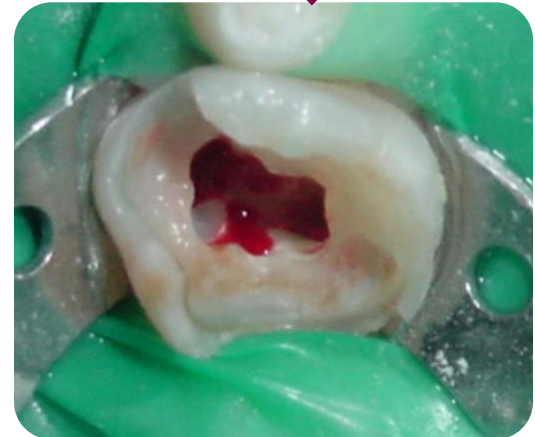
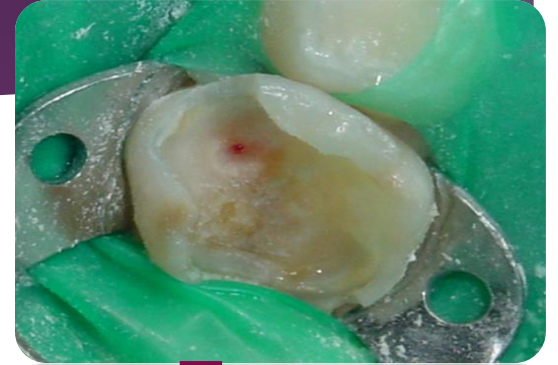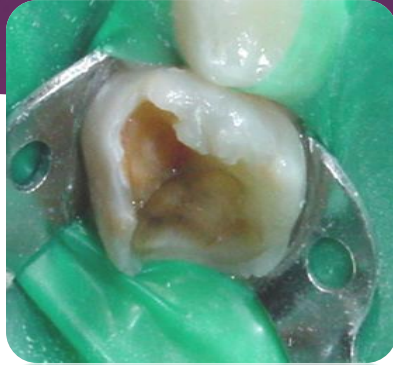

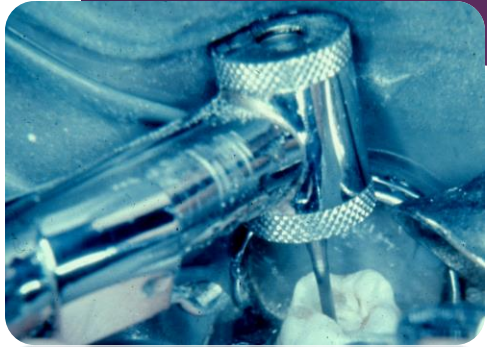
- ▶ Swelling (of pulpal origin)
- ▶ Fistula
- ▶ Pathologic mobility
- ▶ Pathologic external root resorption
- ▶ Internal root resorption
- ▶ Periapical or interradicular radiolucency
- ▶ Pulp calcification
- ▶ Excessive bleeding from amputated radicular stumps



# Pulpotomy Technique

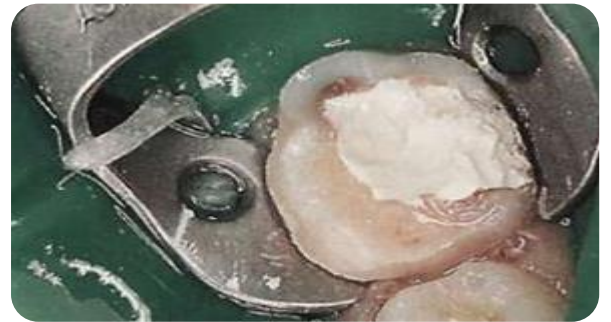

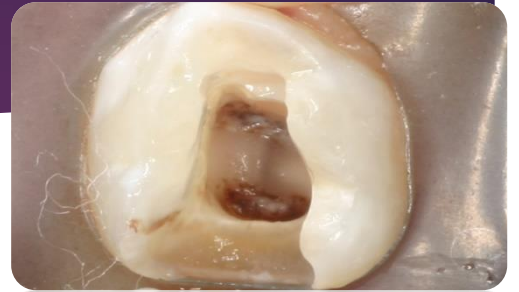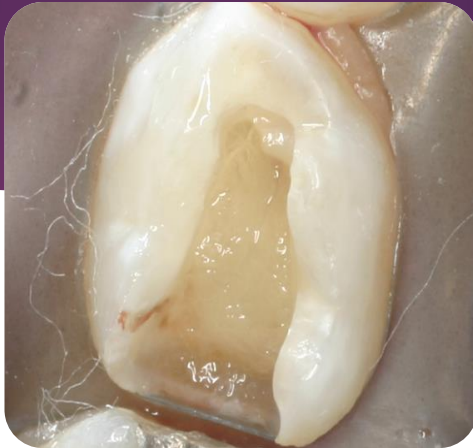
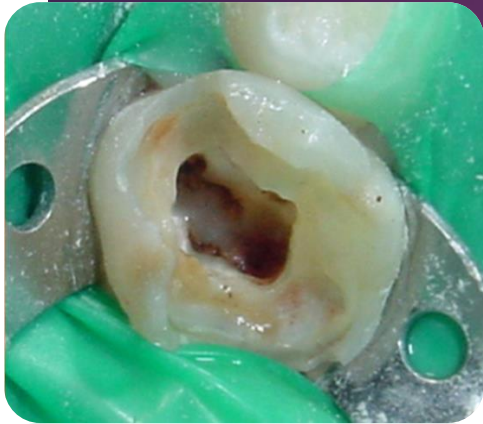- ▶ Anesthesia
- ▶ Caries removal all around the cavity walls
- ▶ Axial wall the final wall for caries removal
- ▶ The least amount of infected dentin when the exposure happens
- ▶ Roof of pulp chamber removed by dental 330 bur water

cooled high speed joining the pulp horns



# Pulpotomy Technique

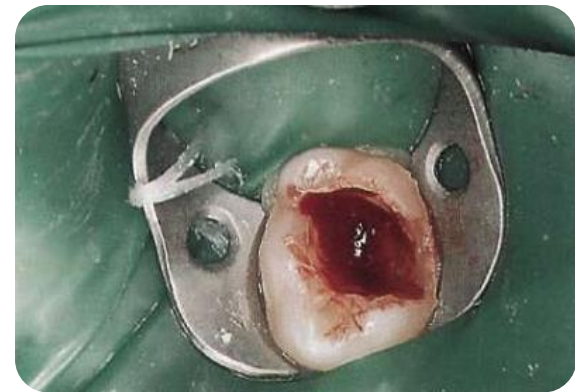- ✓ Coronal pulp removal by sharp excavator or slowly revolving large round bur
- ✓ Pulpal floor perforation
- ✓ No tags of tissue
- ✓ Cotton pellets over amputation sites for a few minutes
- ✓ Hemostasis or minor bleeding
- ✓ Buckley's solution 5 min or 1 min (no contact with gingival tissues)
- ✓ Dark brown or dark red
- ✓ Pulp chamber dried with new pellets
- ✓ A thick paste of ZOE
- ✓ SSC





# Pulpotomy

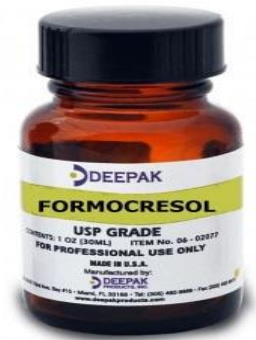- ▶ Pain: insufficient anesthesia or hyperemic pulp
- ▶ Excessive bleeding persist in spite of cotton pellet pressure or deep purple color of tissue



# Ideal Dressing for Radicular Pulp

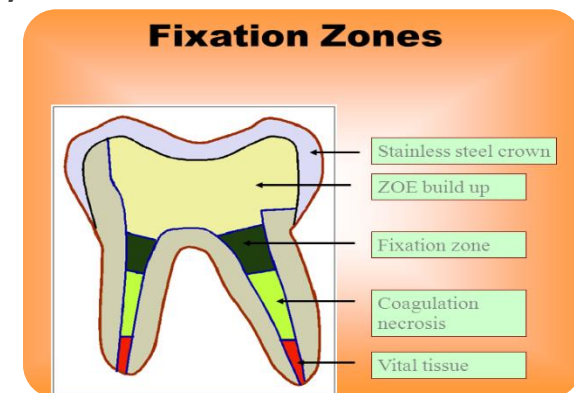
- ✓ Bactericidal
- ✓ Harmless to pulp and surrounding tissues
- ✓ Promote healing of radicular pulp
- ✓ No interfere with physiologic root resorption
- ✓ unfortunately the “ideal” pulp dressing material has not yet been identified.

# Buckley Solution

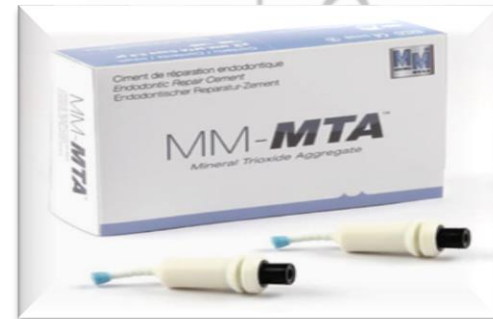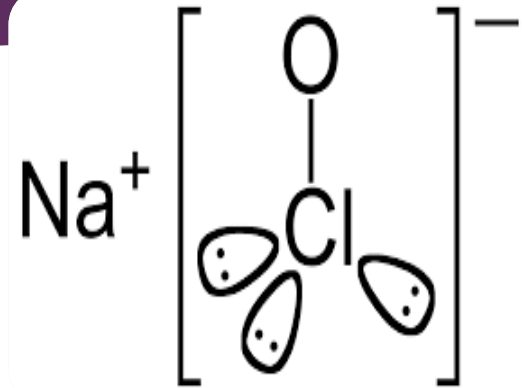

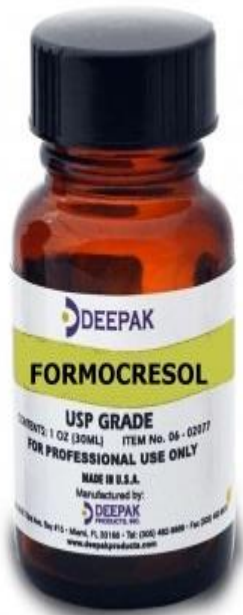
- ✓ Clinical and radiographic success rates : ranging from 70% to 97%.
- ✓ FC is potentially mutagenic, carcinogenic and toxic
- ✓ The doses used in animal models far exceed those used in clinical practice;
- ✓ normal clinical doses carry little risk for patients.

- ✓ A classic study claims that, subsequent to formocresol application, fixation occurs in the coronal third of the radicular pulp, chronic inflammation in the middle third, and vital tissue in the apical third.
- ✓ Others report that the remaining pulp tissue is partially or totally necrotic.



# Potential substitutes for FC



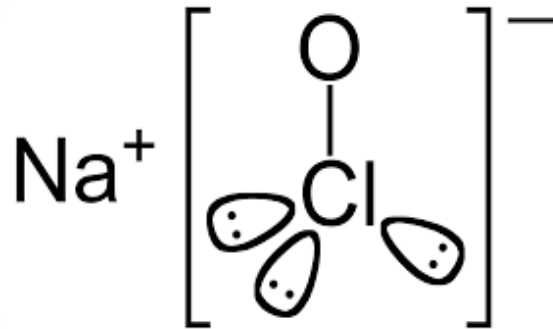
# Glutaraldehyde 2%

- ▶ Glutaraldehyde 2%
- ▶ mild fixative
- ▶ cross linking properties,
- ▶ limited penetration into periapical tissues
- ▶ short-term success of 2% GA as a pulpotomy agent has been demonstrated in several studies.
- ▶ longer-term success rates matching those of formocresol have not been reported.

# NaOCL 5%

▶ studies:

- ✓ clinical and radiographic success rates for NaOCl pulpotomies are comparable to FS and formocresol pulpotomies.
- ▶ further studies with longer observation periods are needed



# Ferric Sulfate

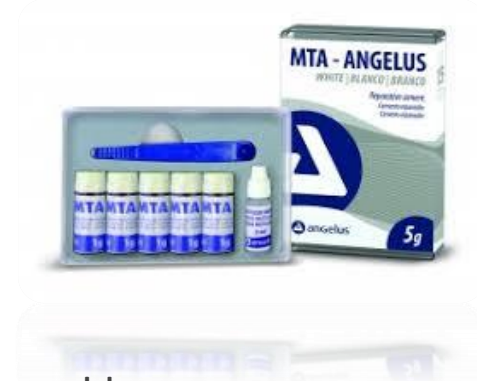

- ▶ 15.5% Astringent
- ▶ agglutinates blood proteins and controls hemorrhage in the process without clot formation.
- ▶ FS may be recommended as a suitable replacement for formocresol.
- ▶ FS can still be an appropriate and inexpensive solution for pulpotomies in primary teeth.



# MTA

- ▶ Portland cement, dicalcium silicate, tricalcium silicate, tricalcium aluminate, gypsum, and tetracalcium aluminoferrite; bismuth oxide (opaque)
- ▶ **many positive properties such as**
  - ✓ excellent biocompatibility,
  - ✓ alkaline pH
  - ✓ radiopacity
  - ✓ high sealing capacity
  - ✓ ability to induce the formation of dentin, cement, and bone.



# MTA

- ▶ MTA: Gray or White
- ▶ White MTA no tetracalcium aluminoferrite
- ▶ Dentin bridge formation significantly better with gray MTA compared to white MTA
- ▶ The gray MTA had 100% radiographic success, and the white had a 93% success rate.
- ▶ The negative attributes include:
  1. difficulty of handling
  2. the exceptional cost.

# Portland Cement :

- ✓ no bismuth ion and presence of potassium ion
- ✓ compared PC, MTA : Both materials have comparable antibacterial activity and almost identical properties macroscopically, microscopically
- ✓ compared the success rates of PC, MTA, formocresol in primary molar pulpotomies and found similar clinical and radiographic effectiveness after 24 months.
- ✓ before routine clinical use of PC can be recommended, further studies with large samples and long follow-up assessments are needed.

# Nonpharmacotherapeutic Approaches :



Laser

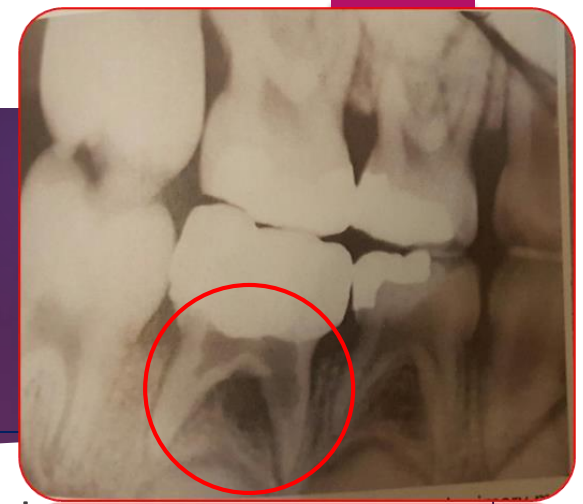

# Summary

- ✓ alternatives to formocresol as a pulp dressing in primary tooth pulpotomies has yet to reveal an ideal agent or technique.
- ✓ formocresol (either in a 1/5 or full strength), FS, or MTA can be used as capping agents in primary tooth pulpotomies.

# Vital Pulp Therapy Failures

# Internal Resorption



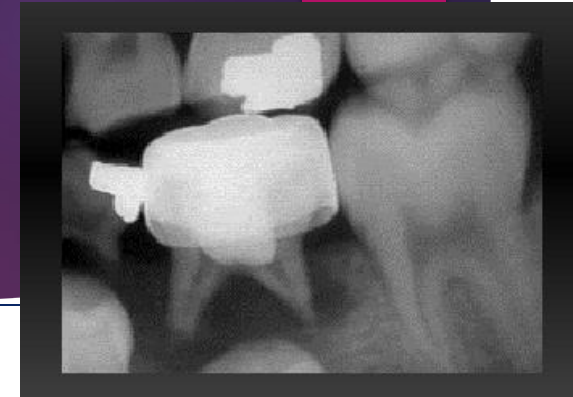- ▶ the most frequently seen evidence of an abnormal response
- ▶ Radiographic evidence of internal resorption occurring within the pulp canal several months after the pulpotomy procedure
- ▶ Internal caused by odontoclastic activity
- ▶ progress slowly or rapidly
- ▶ Occasionally, secondary repair of the resorbed dentinal area occurs.

# Internal Resorption

- **that with a true carious exposure of the pulp, an inflammatory process will be present to some degree.**
- ▶ abnormal pulp tissue may be allowed to remain.
- ▶ If the inflammation extended to the entrance of the pulp canal, odontoclasts may have been attracted to the area;
- ▶ tooth histologically : small bays of resorption would be evident.
- ▶ This condition may exist at the time of pulp therapy,
- ▶ although there is no way to detect it.
- ▶ The only indication would be the clinical evidence of a hyperemic pulp.
- **internal resorption even though the pulp is normal at the time of treatment :**
- ✓ Inflammatory cells drawn to the area as a result of the placement of an irritating capping material might well attract odontoclastic cells and initiate internal resorption.



# Alveolar Abscess



- ✓ occasionally develops some months after pulp therapy
- ✓ The tooth usually remains asymptomatic
- ✓ the child is unaware of the infection, which may be present in the bone surrounding the root apices or in the area of the root bifurcation.
- ✓ A fistulous : indicates the chronic condition of the infection.
- ✓ **Primary teeth** : should be removed.
- ✓ **Permanent teeth** : that have previously been treated by pulp capping or by pulpotomy and later show evidence of pulpal necrosis and apical infection may be considered for endodontic treatment.

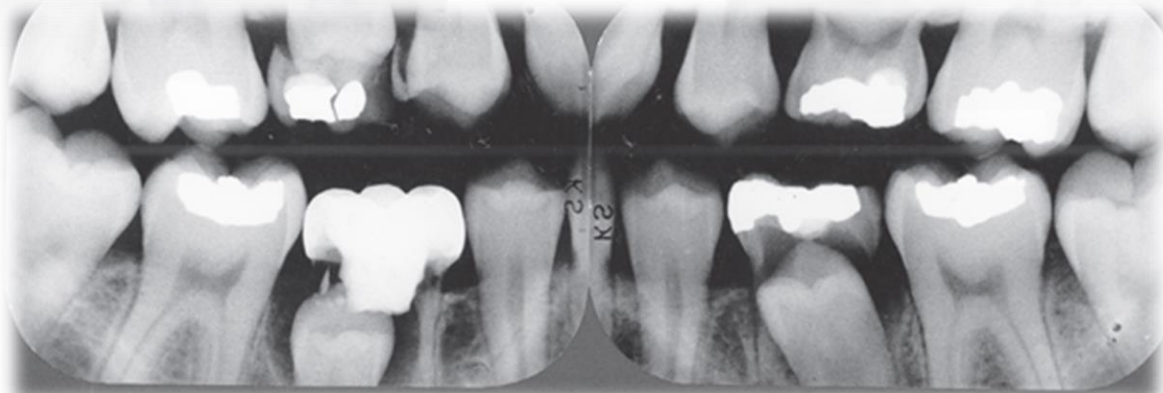
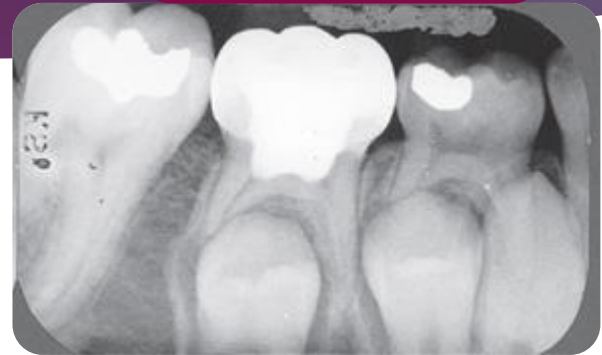
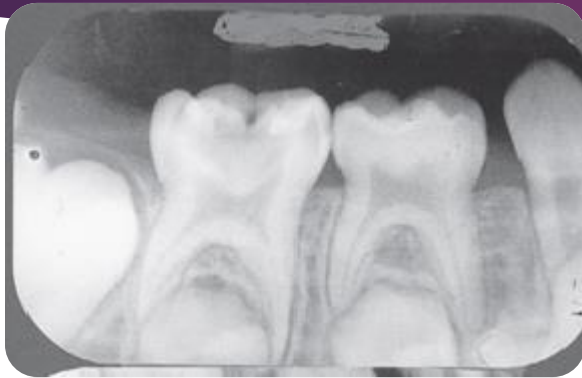# Early Exfoliation

- ❑ **loosen and exfoliate (or require extraction) :**
- ✓ It is believed that such a condition results from low-grade, chronic, asymptomatic, localized infection.
- ✓ abnormal and incomplete root resorption patterns of the affected teeth are also observed.

# Over-Retention

- ✓ **tendency for primary teeth undergoing successful pulpotomies or pulpectomies to be over-retained.**
- ✓ result of interfering with the normal eruption of permanent teeth and adversely affecting the developing occlusion.
- ✓ Extraction of the primary tooth is usually sufficient.
- ✓ normal physiologic exfoliation is delayed by the bulky amount of cement contained in the pulp chamber.

4 years later



7 years later



THANK YOU

FOR YOUR

ATTENTION